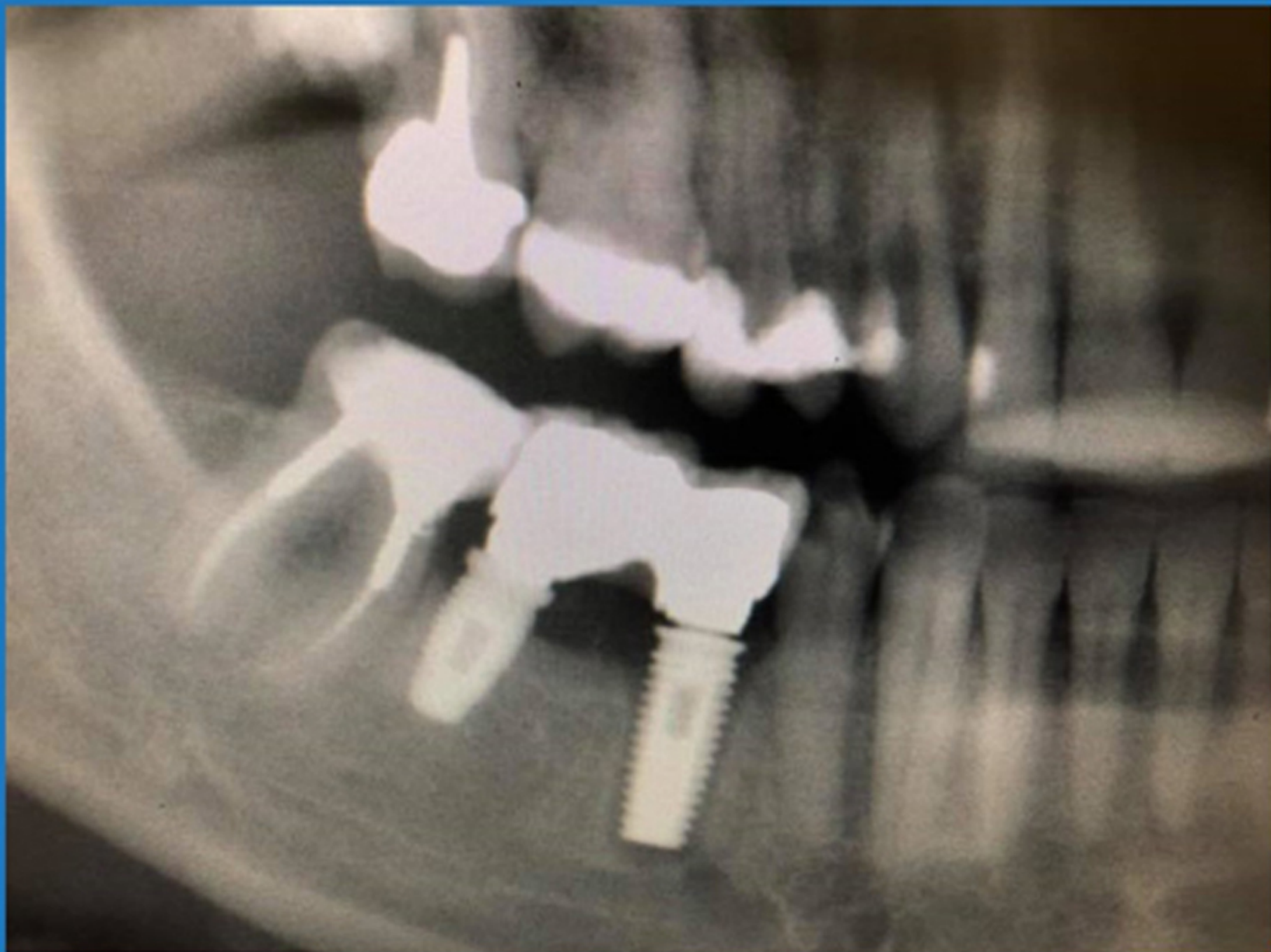


# Periimplantitis Clinical Case with Augma Bond Apatite®

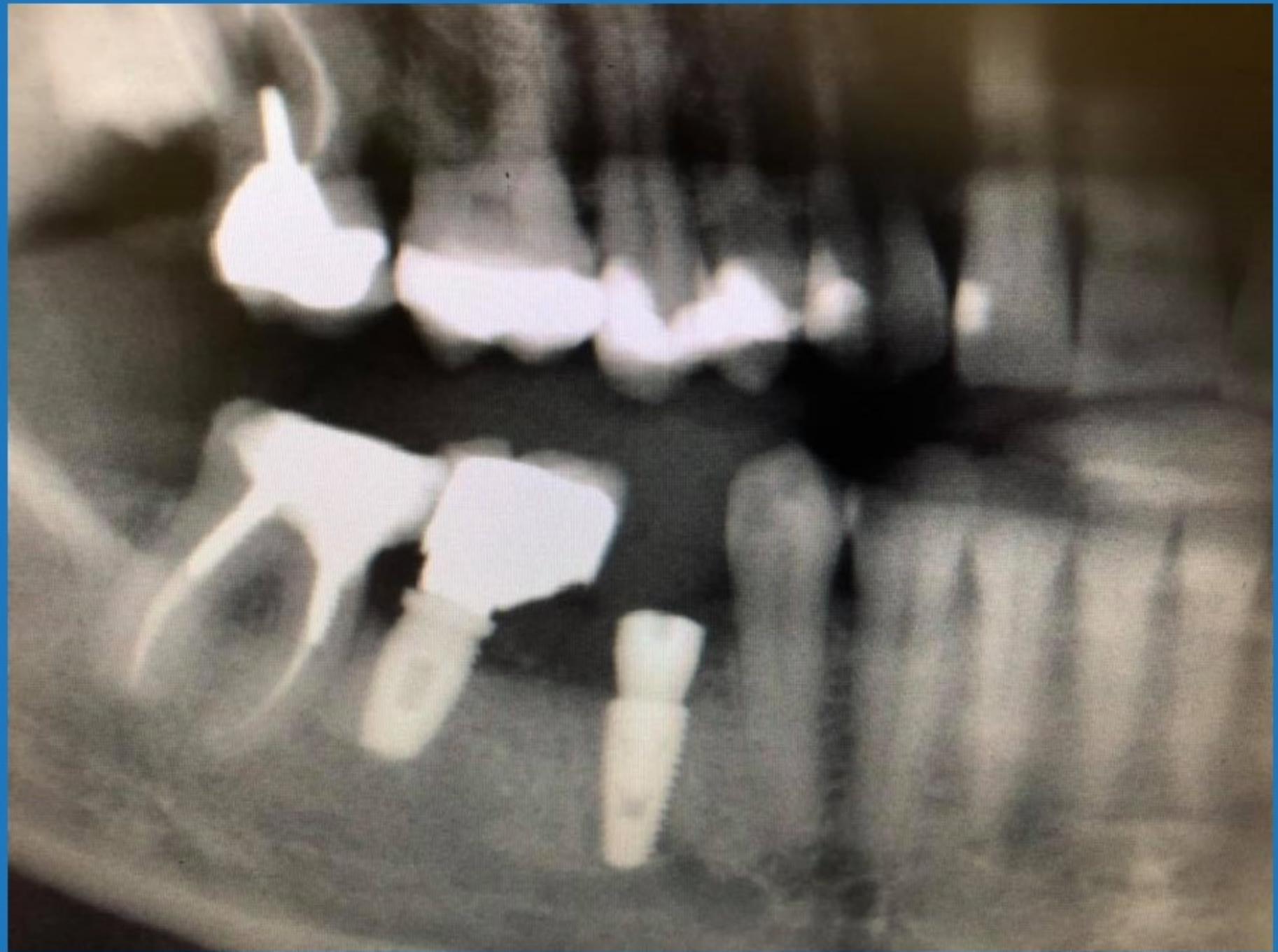**Dr. Peter Morbach**



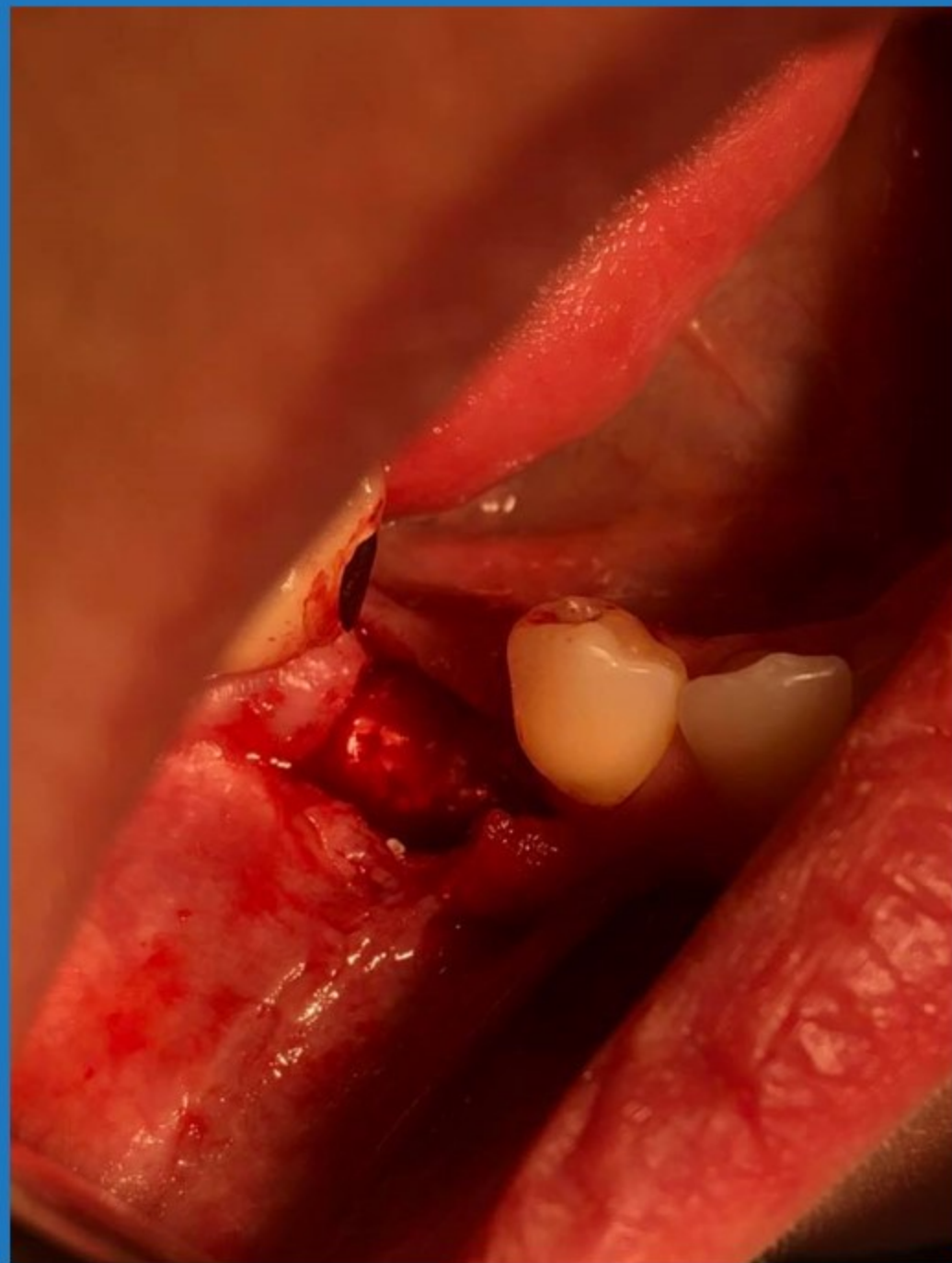Pre-Op



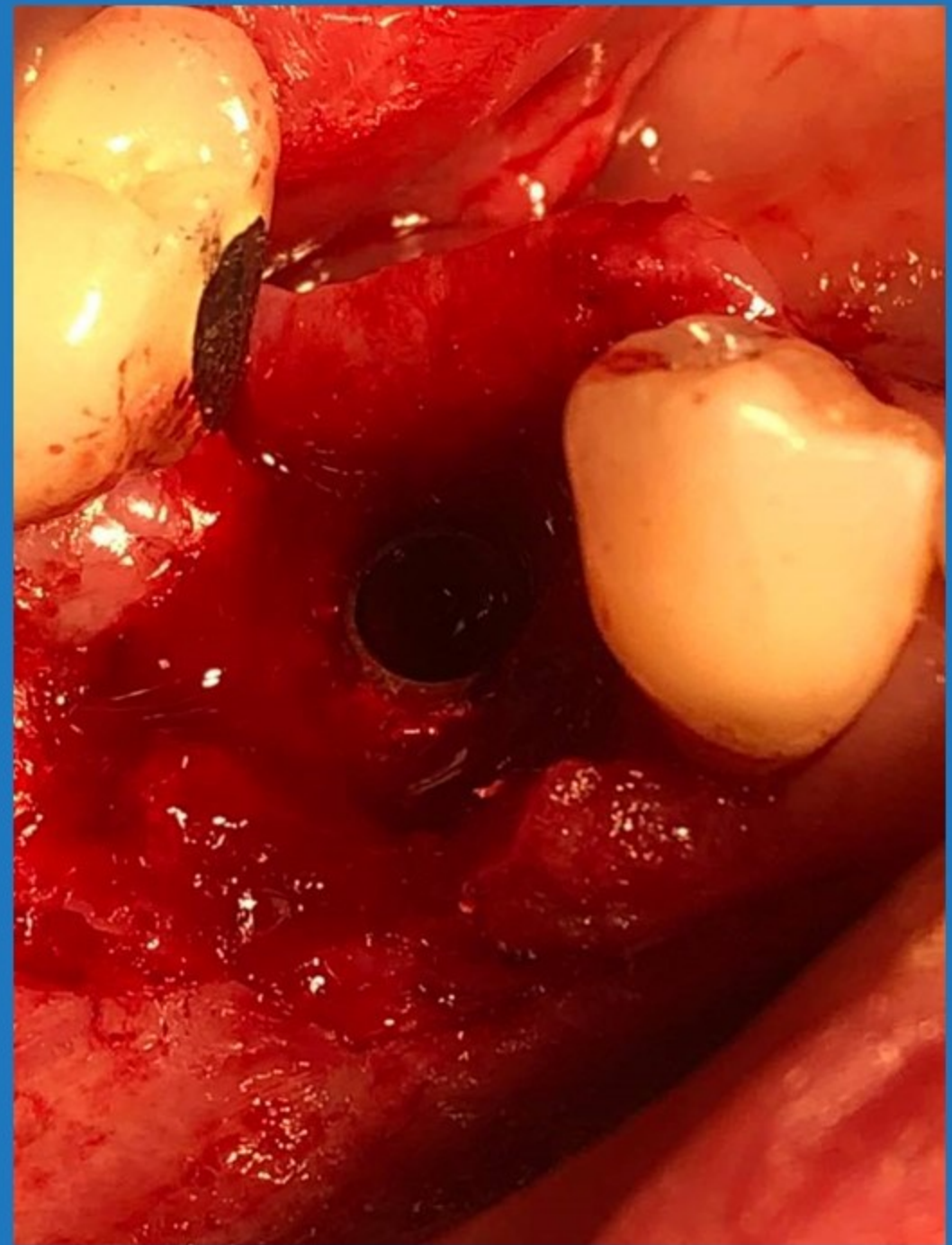Pre-Op



Post-Op



Post-Op



Post-Op

