

Bond apatite[®]

*is a composite graft made of biphasic calcium sulfate and HA in a specific particle size distribution, in a ratio of 2:1. This combination takes advantage of each part of its components. Calcium sulfate acts as a short-range space maintainer scaffold; **it completely degrades in a strict relation with the bone formation rate**, (4-10 weeks) while the HA acts as a long term space maintainer. The amount of HA within the graft is in a relatively small proportion (33%) in a controlled particle size distribution and is intended only to slow down the overall resorption of the graft. The small and medium size of the HA particles resorbs as well in 4-6 months while the large particles which are about 10% remain in the grafted site for longer period.*

The bioactivity and the rapidly graft transformation into vital bone is due to the biphasic calcium sulfate that is 66.6% of the graft. The calcium sulfate encourages angiogenesis, osteoblastic activity, enhanced calcification and is completely degraded and replaced with the patient's own bone

.


.

Bond Apatite® has macro and micro porosity that is required for nutrient and cell transfer to the scaffold center. Also, calcium sulfate degradation allows bone growth and angiogenesis during healing. •

At implantation the HA granules within Bond Apatite are covered by the cemented biphasic calcium sulfate matrix, however, with time, the calcium sulfate matrix degrades thus increasing its porosity and liberates space for the new bone formation between the hydroxyapatite particles which hold the structure and preserve the volume during the healing phase •

Due to the fact that the HA particles have a specific PSD, the small size particles degrade as well, and are replaced by the patient's own bone within relatively short amount of time. •


SEM image of Bond Apatite® after setting (x40 magnification)



HV	WD	Mag	Det	Sig
15.0 kV	12.5 mm	40x	SSD	BSE

2.0mm
CG 7


Internal porosity structure are divided into macro and micro porous (x1000 magnification.)



HV	WD	Mag	Det	Sig
15.0 kV	10.5 mm	1000x	SSD	BSE

100.0μm
CG 6

Micro porosity (x4000 magnification)



HV	WD	Mag	Det	Sig
15.0 kV	10.5 mm	4000x	ETD	SE

20.0µm
CG 6


The radiographic images, presented in the following clinical cases, demonstrate the different resorption behavior of each matrix. The biphasic calcium sulfate matrix is progressively and completely degraded and replaced by new osteoid formation. The osteoid in the first stage is uncalcified, hence it appears radiolucent; however gradually recalcification of the osteoid is taking place and radiopacity appears. The HA, on the other hand, remains radiopaque. The HA particles act as a long range space maintainer and remain incorporated within the newly formed bone matrix.

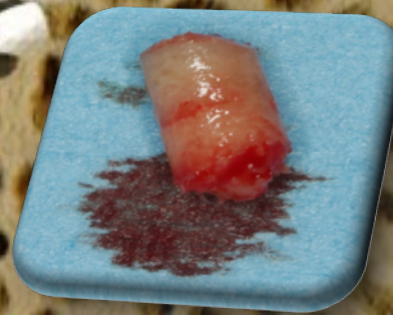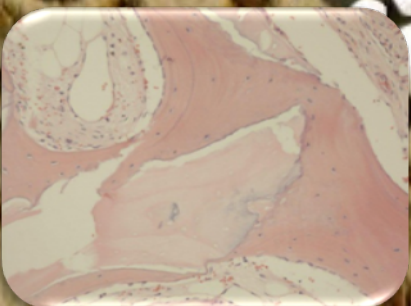
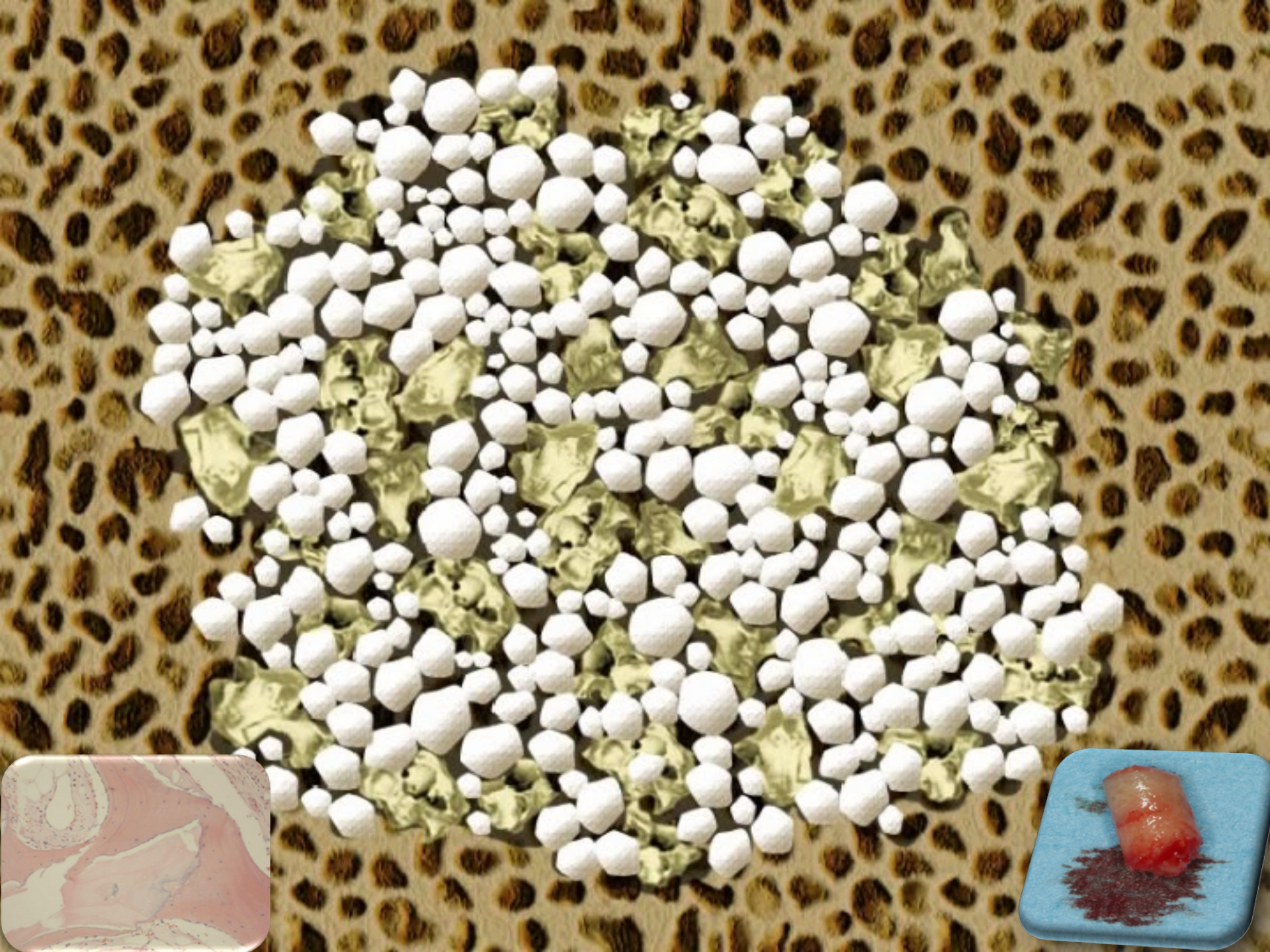
Comparison of augmentation outcome, when using HA alone from bovine origin (Bio- Oss®) versus composite graft (Bond Apatite®)

Using a long range space maintainer can lead to good 3D space preservation. Nevertheless, the bone quantity and quality is poor and limited into the gaps in between the HA granules.

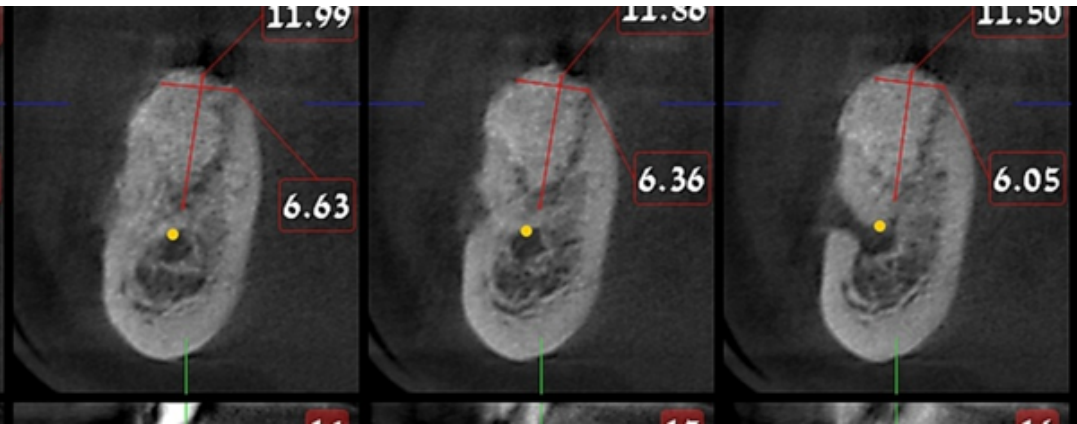
In order to increase the amount of the new bone formation, as well preserving the 3D volume, a composite graft combines two different matrixes with diverse degradation pattern should be used. One that has a long range space maintaining ability (for maintaining the three dimensional volume), and the second with a short range of space maintaining (for increasing the amount of a new bone formation).

*The following slides illustrate concretely the differences in the final outcome :
when using HA granules alone, from bovine origin in this case (Bio-oss®) [figs. 1,2]
versus using a prefabricated composite graft made of Biphasic calcium sulfate with synthetic HA particles (Bond Apatite®) [figs.3,4]*

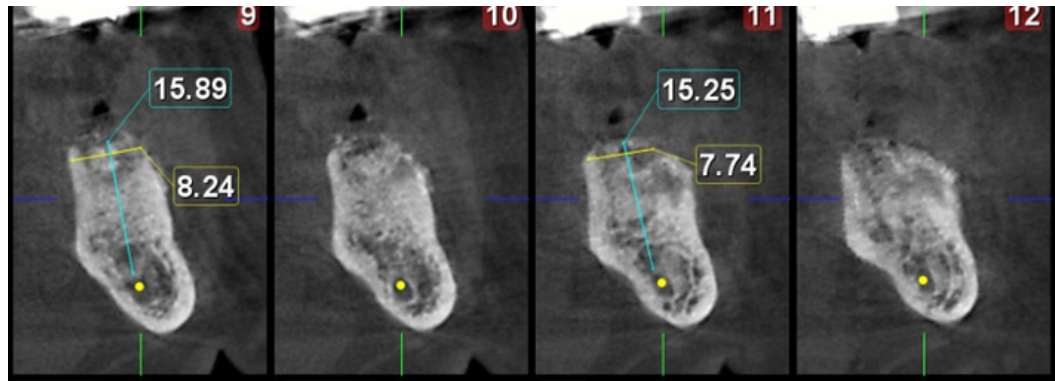




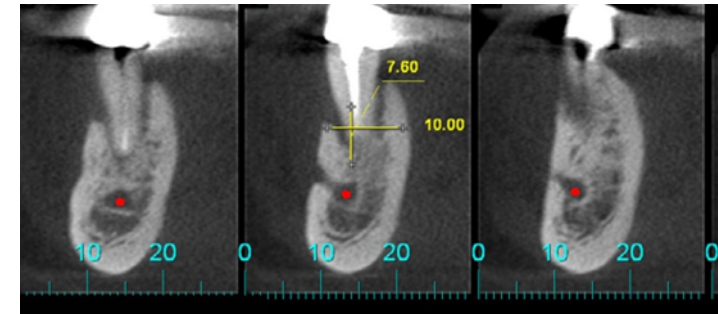
Comparison of augmentation outcome when using HA from bovine origin alone (Bio-oss®) [figs.1,2] and Bond Apatite® [figs. 3,4]



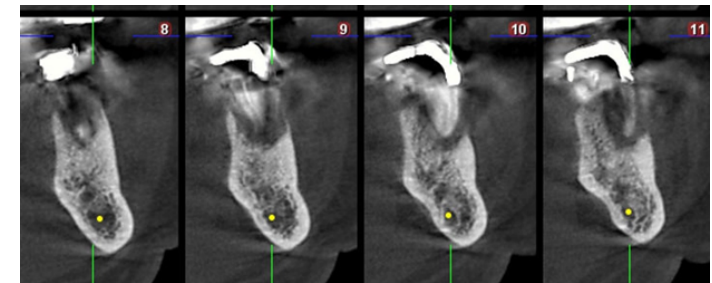
2. 24 weeks post op. the quantity of vital bone formation is limited into the spaces in-between the HA granules (Augmentation with Bio-Oss®)



4. 12 weeks post op, new bone formation completely replace the Biphase calcium sulfate matrix, while the HA granules are incorporated within the new bone matrix (Augmentation with Bond Apatite®)



1.Before augmentation



3.Before augmentation

Case #1

Patient 54 years old female

This case presents a large bone distraction after removal of hopeless tooth 45 46 47 (Figs. 1.2.3.4) Tooth were removed followed by a thorough debridement and augmentation procedure simultaneously with implant placement. As bone graft substitute Bond apatite® was used (Fig. 5), soft and hard tissue healing was uneventfully (Fig 6.7)and reentry, 22 weeks Post op, shows an impressive vital bone formation (Fig. 12).

Radiographic images (Figs 8.9.10) demonstrate the degradation pattern of the graft, as well in the CT scan. We can differentiate between the biphasic calcium sulfate matrix that entirely resorb, and replaced with a new bone formation, whereas the HA particles act as a long range space maintainer and remain incorporated within the new formed bone matrix (Fig 13).

Case 1

Augmentation procedure
using Bond Apatite®
in a large 3D defect after
hopeless tooth removal

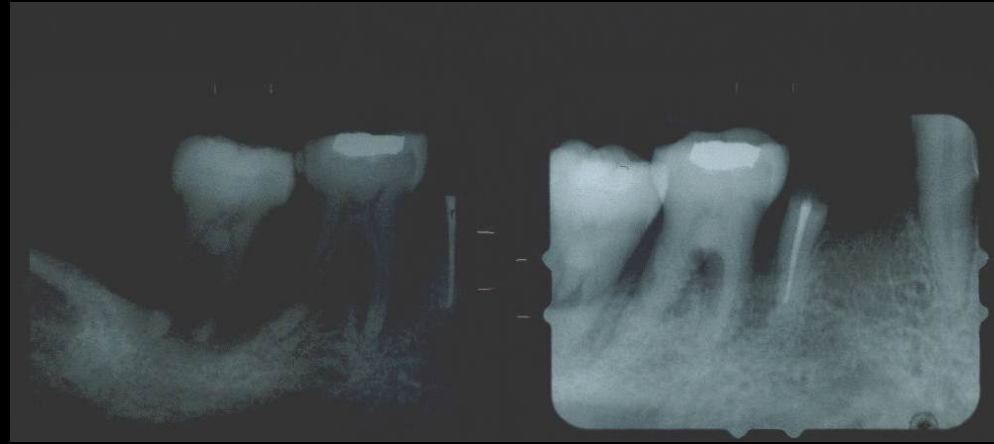

Fig. 1

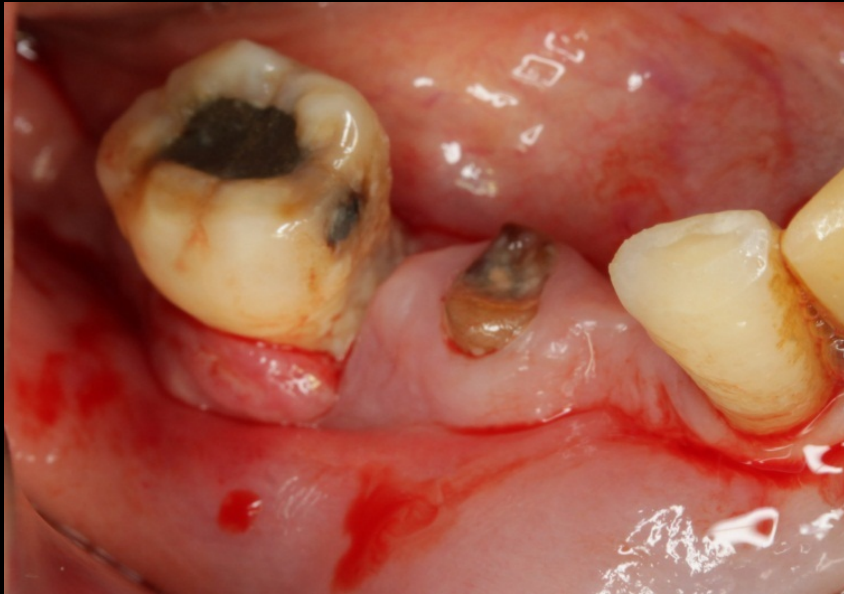

Fig. 2

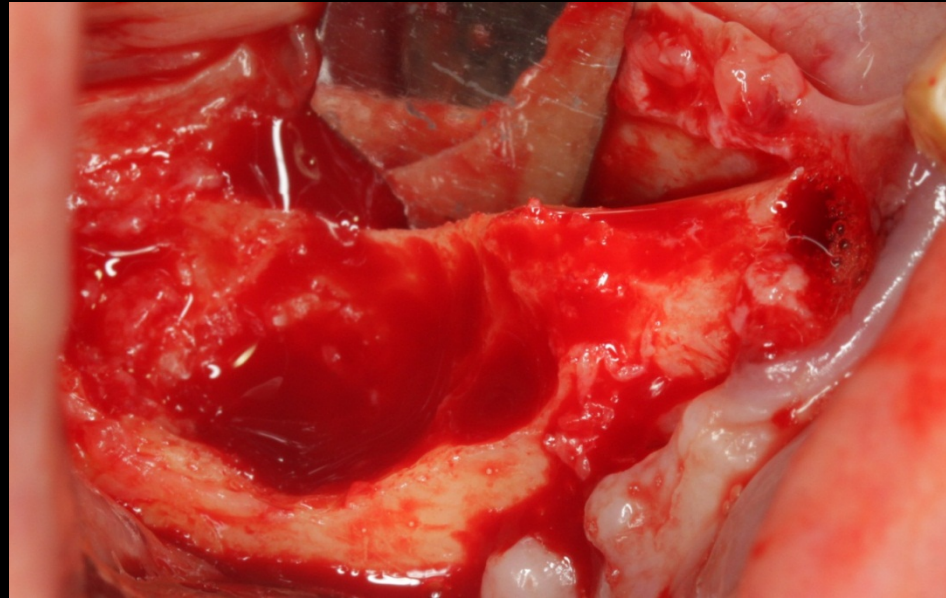


Fig 3.

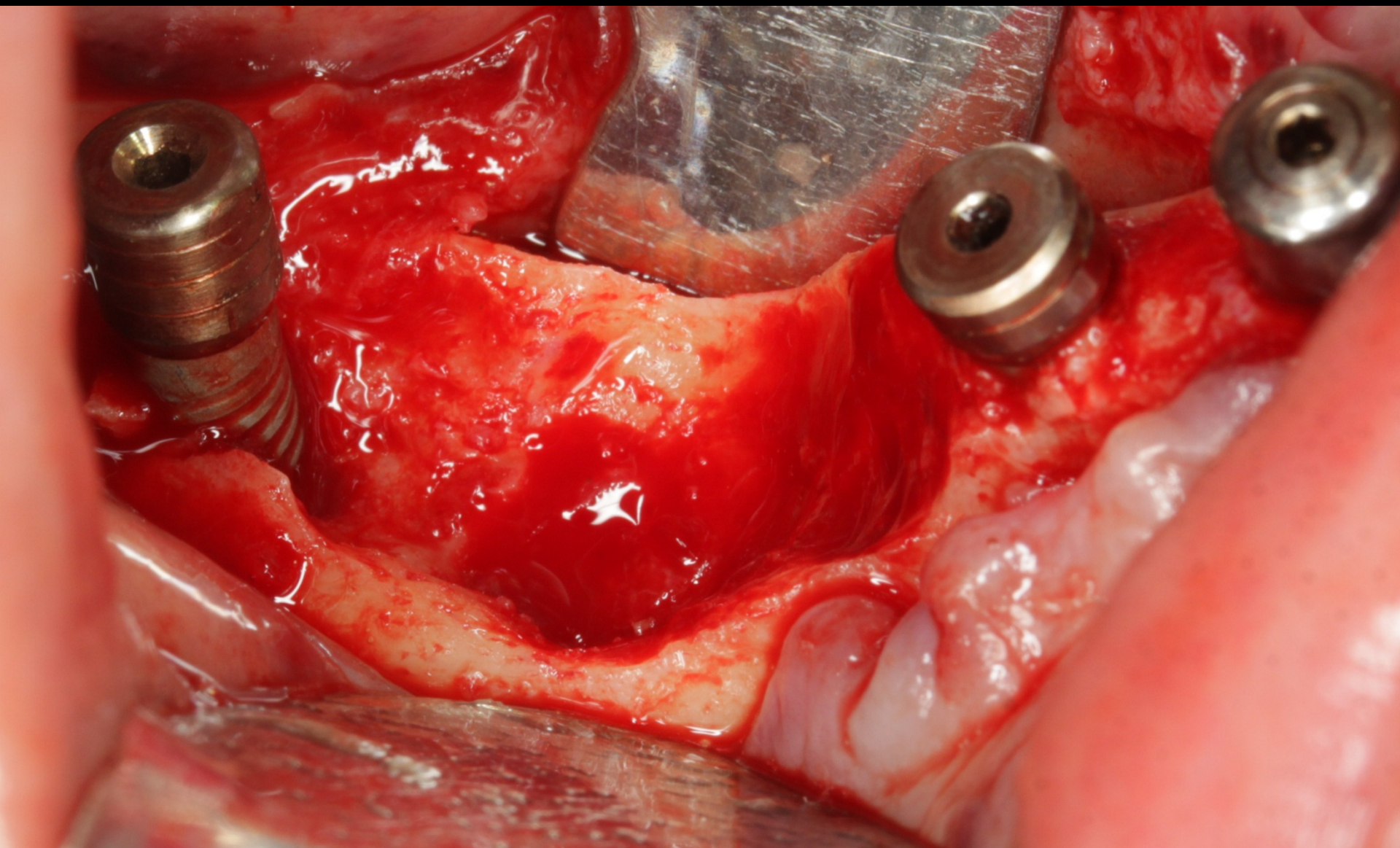


Fig 4

Bond Apatite® application

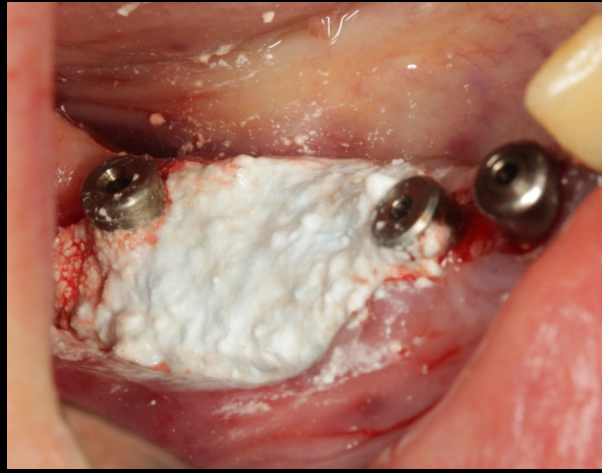
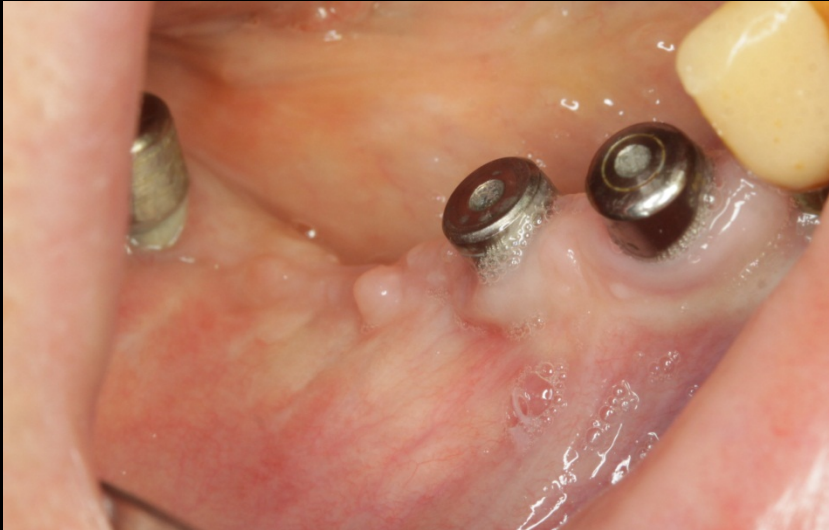
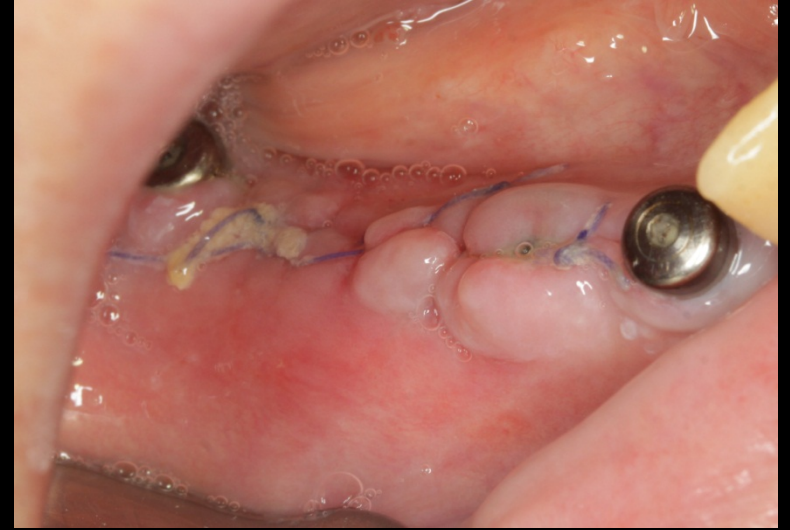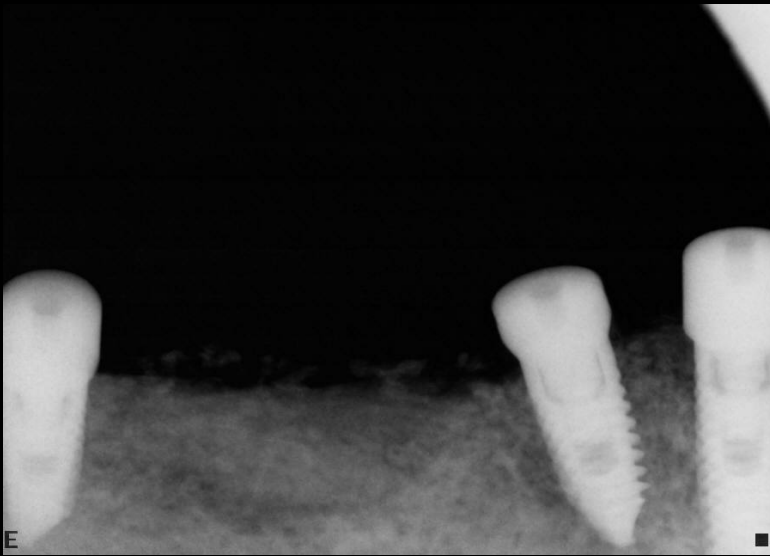
Fig. 5



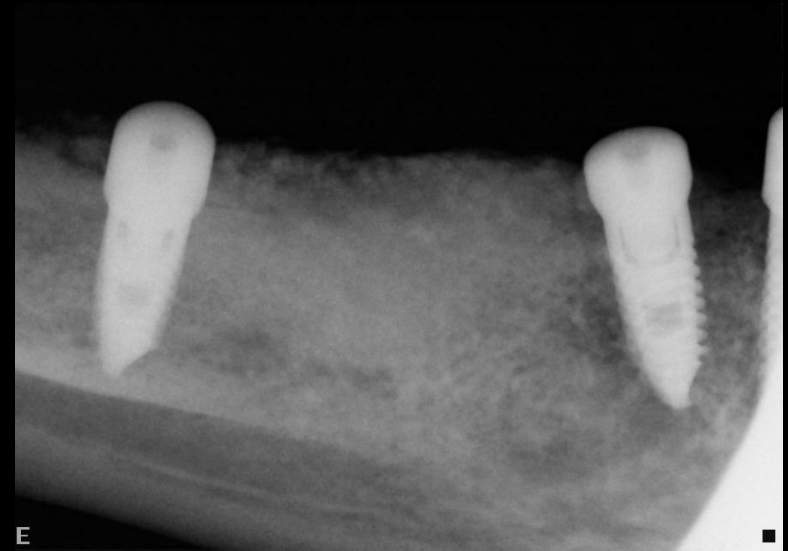12 weeks post op (Fig. 7)



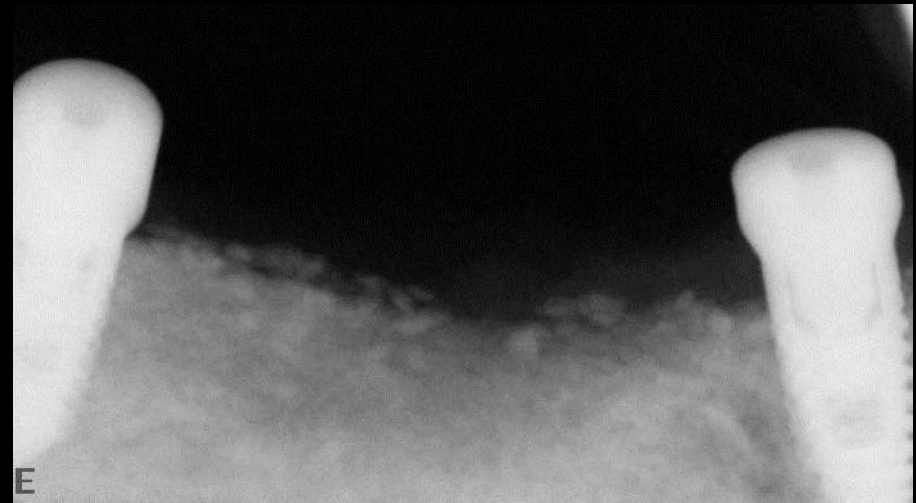
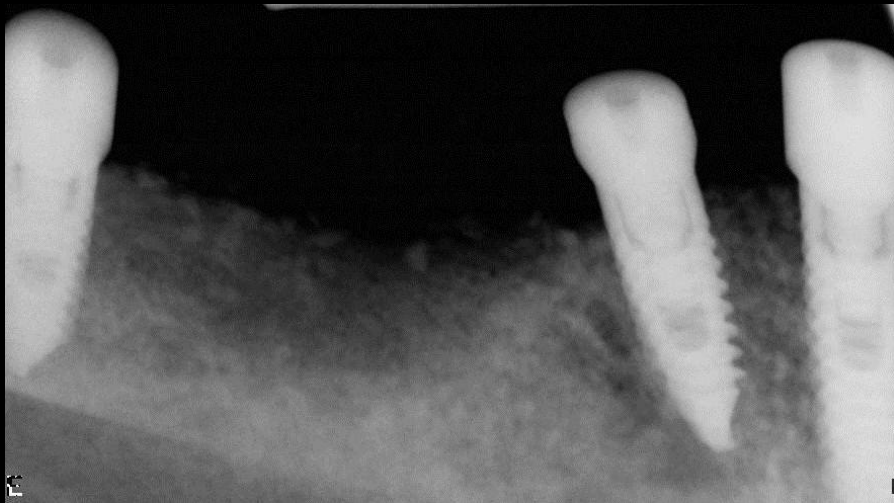7 days post op (Fig. 6)



11 days post op degradation of the biphasic calcium sulfate matrix can be seen(Fig. 9)



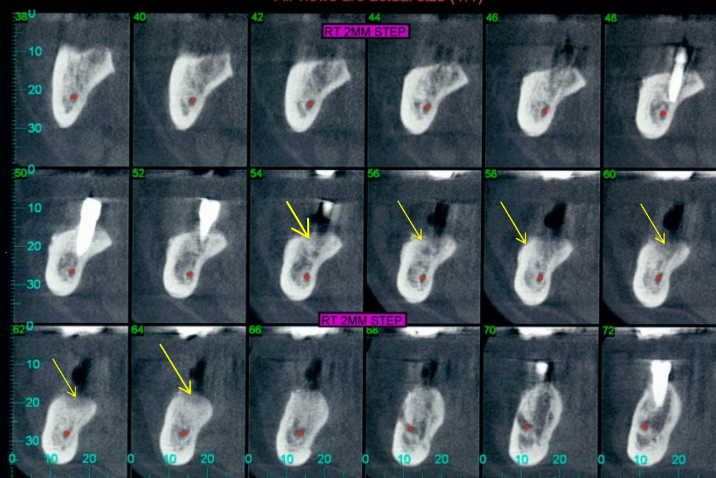
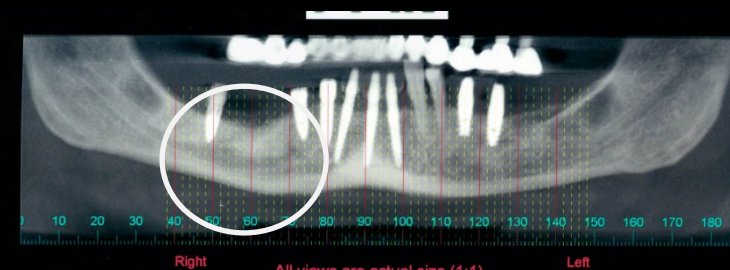
Day 1 after extractions, implants 43 44 48 were placed augmentation in 46 47 area with bond apatite®(Fig. 8)



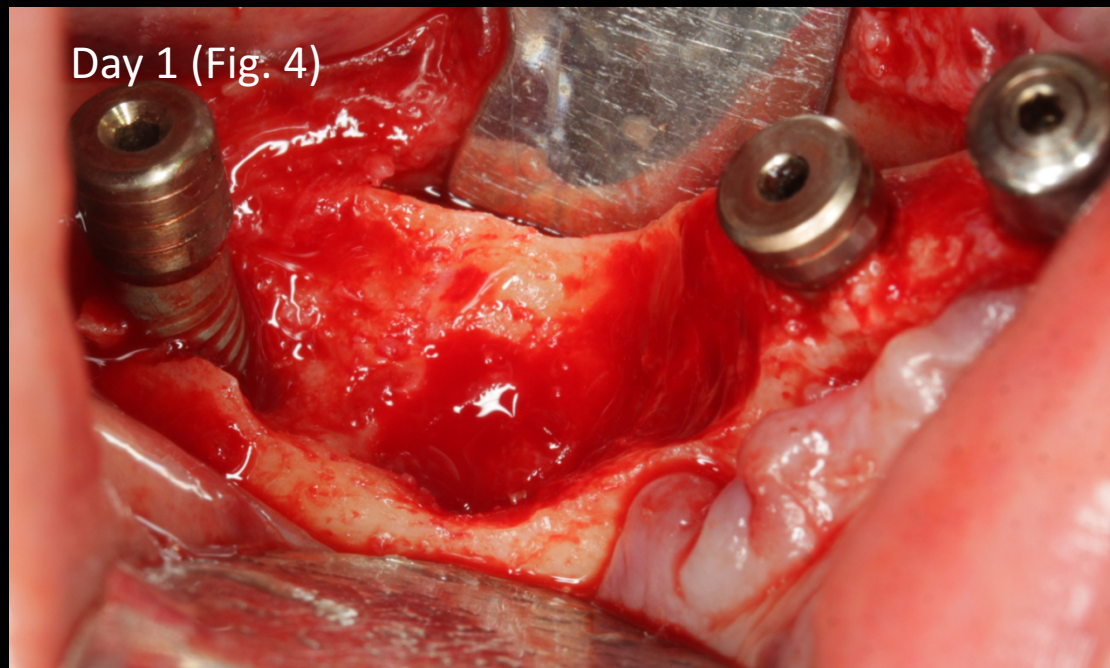
11 weeks post op from 2 different angles radiographs. BCS matrix has been replaced by new mineralized osteoid matrix, while particles of HA are incorporated within the matrix of the new formed bone (Fig. 10)

Fig 13

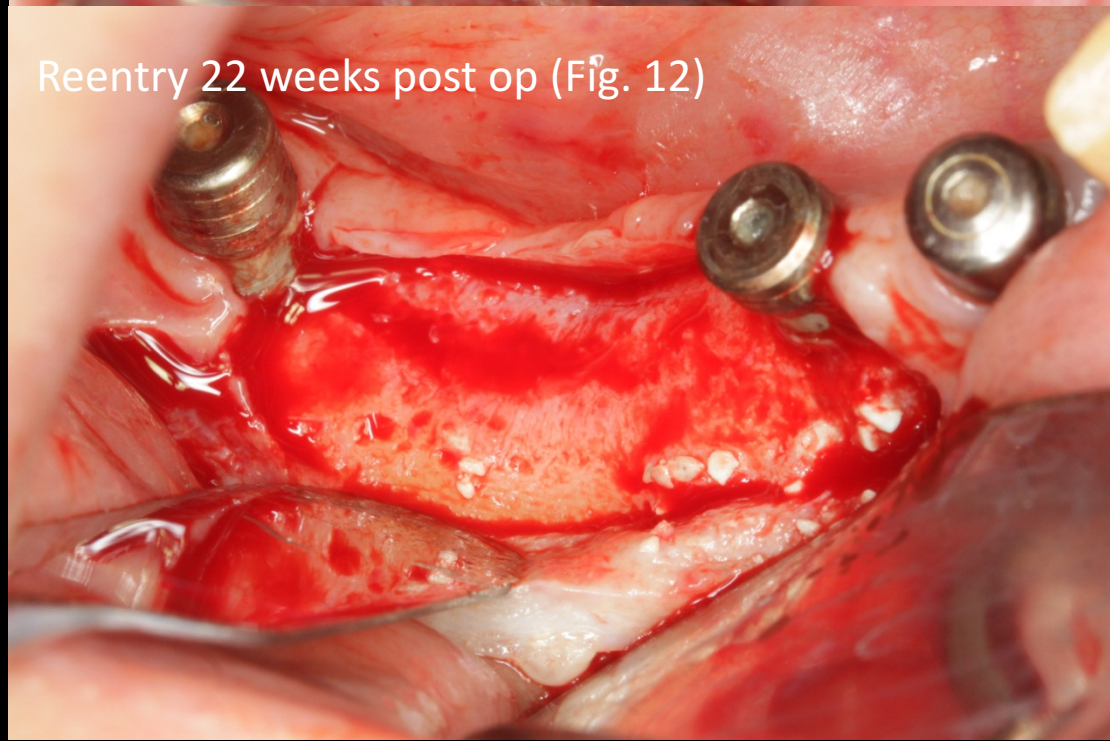
22 weeks post op bone formation
clinically and radiography

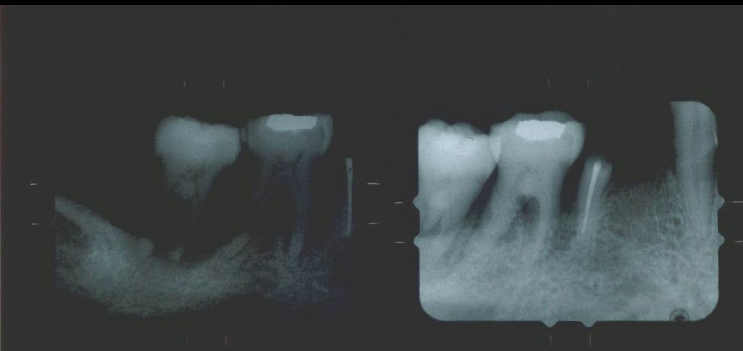


Day 1 (Fig. 4)

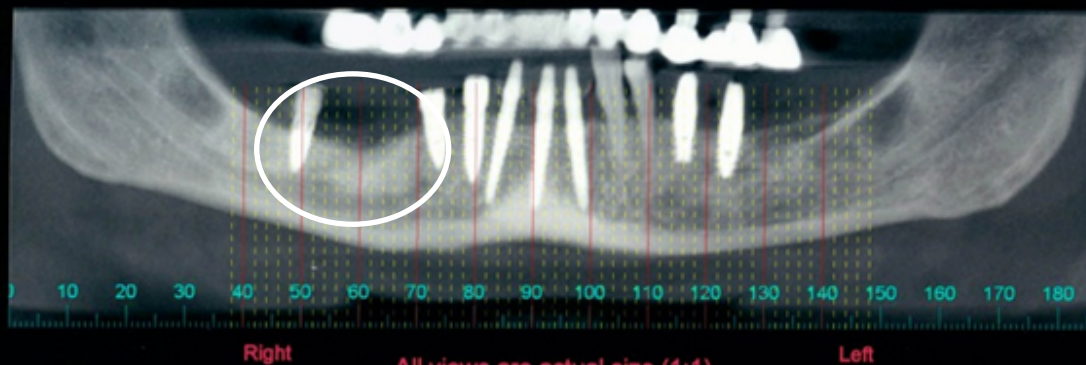


Reentry 22 weeks post op (Fig. 12)

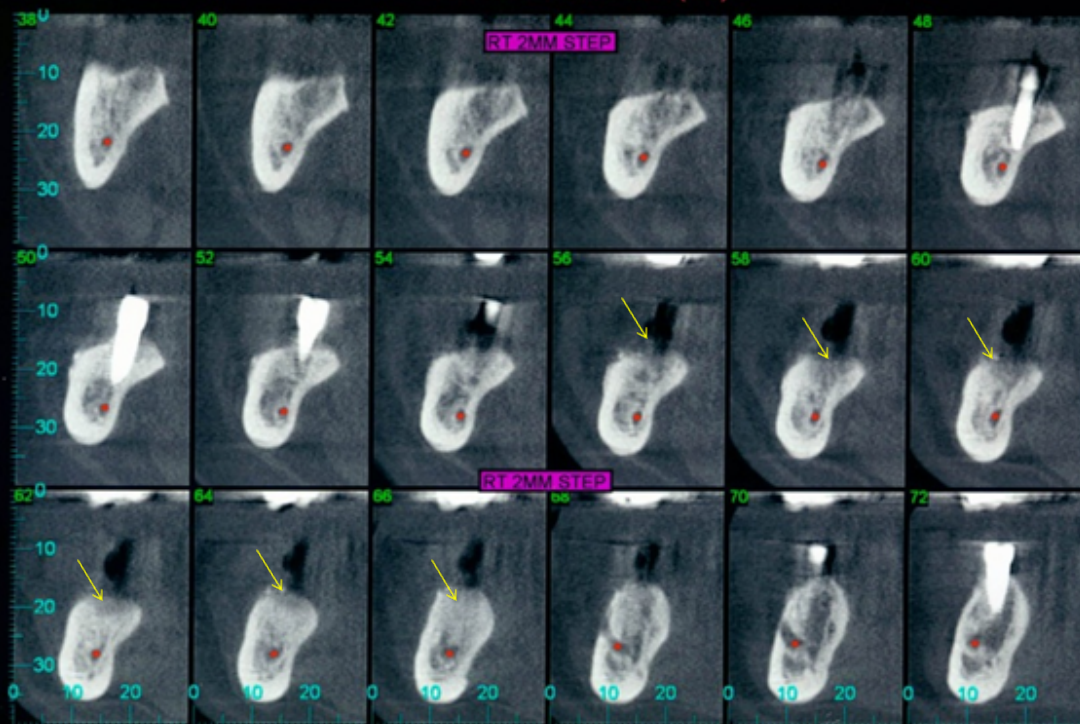




Before extraction



All views are actual size (1:1)



22 weeks post op maturation
of the grafted area

Fig 13



Case #2

Patient: 50 years old female

In this case the treatment decision was to extract the hopeless tooth nr15. A large circumferential bone lesion can be seen in the X-ray image (Fig. 7).

The tooth was extracted (Fig. 1) followed by thorough debridement and augmentation procedure using Bond Apatite® as a bone graft (Fig. 2) covered by an external dressing (Fig. 3)

Healing went uneventfully . 16 weeks post op reentry was preformed and implant was placed.

- (Fig. 4) Displays the soft tissue appearance 16 weeks post op*
- (Fig. 5) Hard tissue appearance at reentry time 16 weeks post op*
- (Fig. 6) Implant in place with good primary consolidation 16 weeks post op .*
- (Fig. 8) Illustrates the radiographic appearance immediately after graft placement.*

At this stage the material appears entirely radio opaque.

- (Fig. 9) Follow up radiographic image was taken 3 weeks post op.*

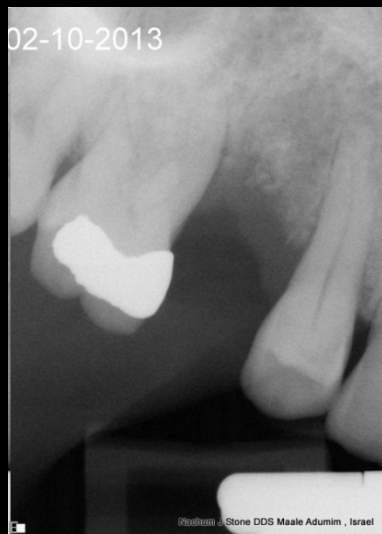At this stage, we can see the grafted area with radiolucent appearance with a floating radio opaque white spots. The radiolucent areas related to the calcium sulfate degradation and new osteoid formation.

During that the radio opaque spots are related to the un degradable HA particles.

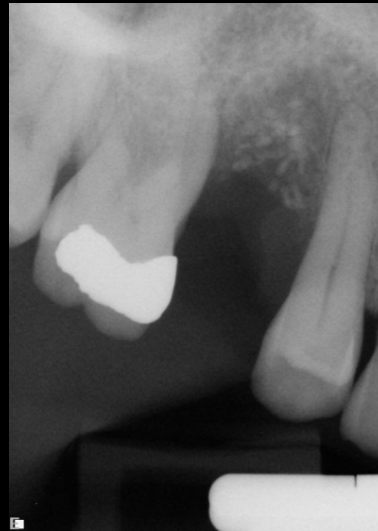- (Fig. 10) Illustrates the radiographic appearance 16 week post op at the reentry time .*

At this stage re-calcification of the new formed osteoid can be seen by increasing the radio opacity intensity

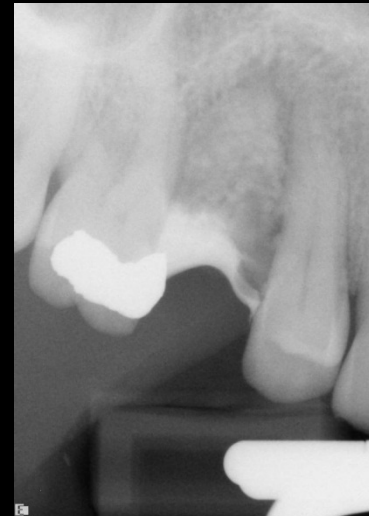
- (Fig. 11) implant in place 16 weeks post op.*



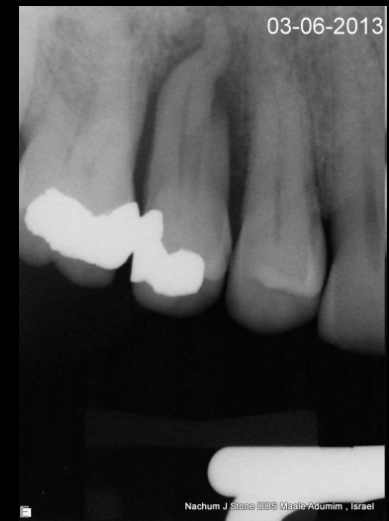16 weeks post op
Re-calcification of
the grafted area
(Fig. 10)



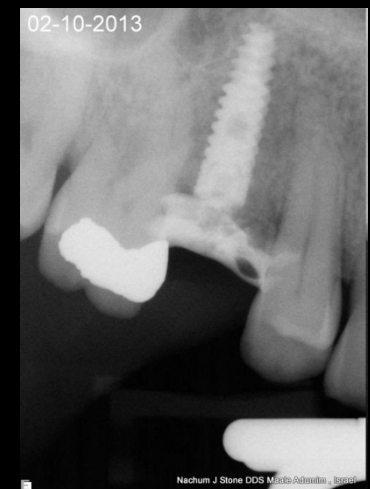
3 weeks post op
degradation of the
Calcium sulfate matrix
(Fig. 9)



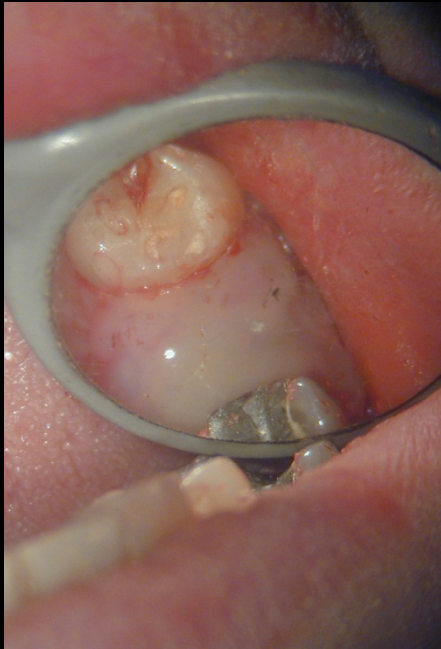Radio opacity appearance
on day one of the Bond Apatite[®]
in place (Fig. 8)



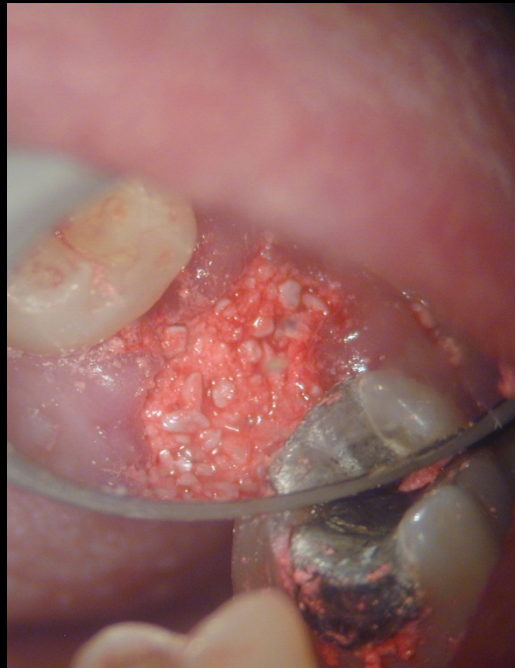Before extraction (Fig.7)



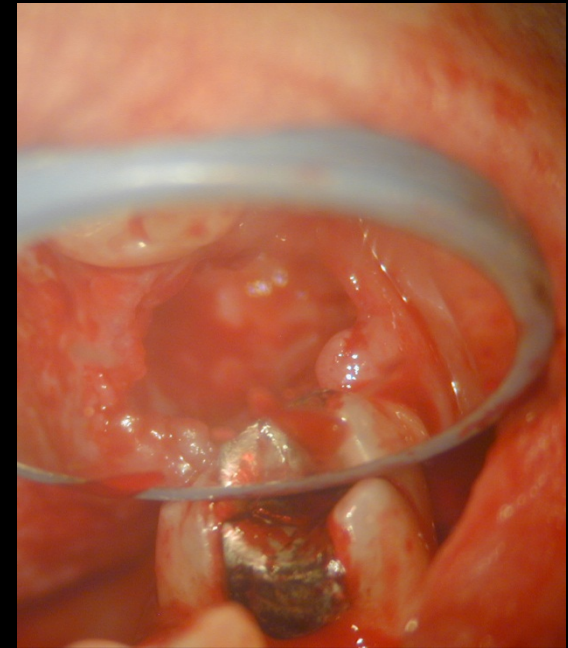
16 weeks post op implant
was placed with good primary
stability (Fig. 11)



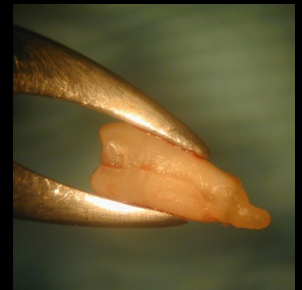External dressing placed
On the grafted area(fig3)

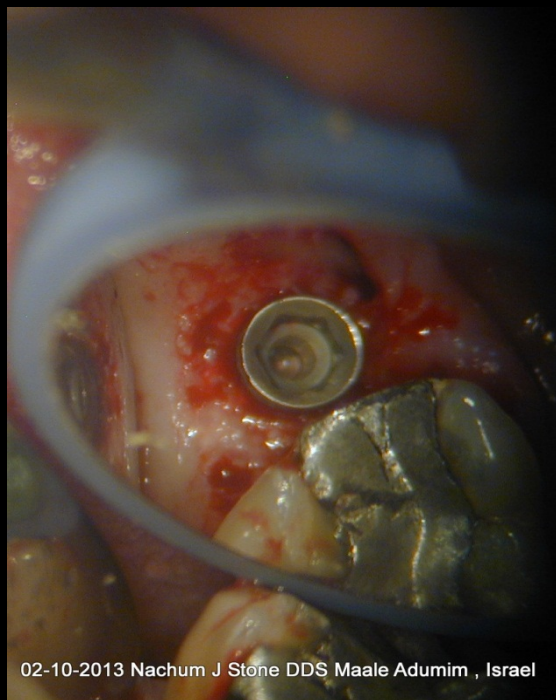


Augmentation using
Bond Apatite(fig2)

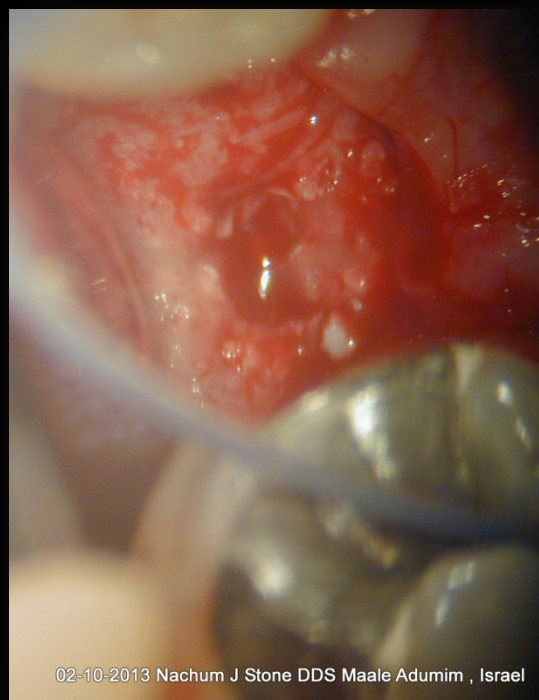


On day 1 after extraction(fig1)

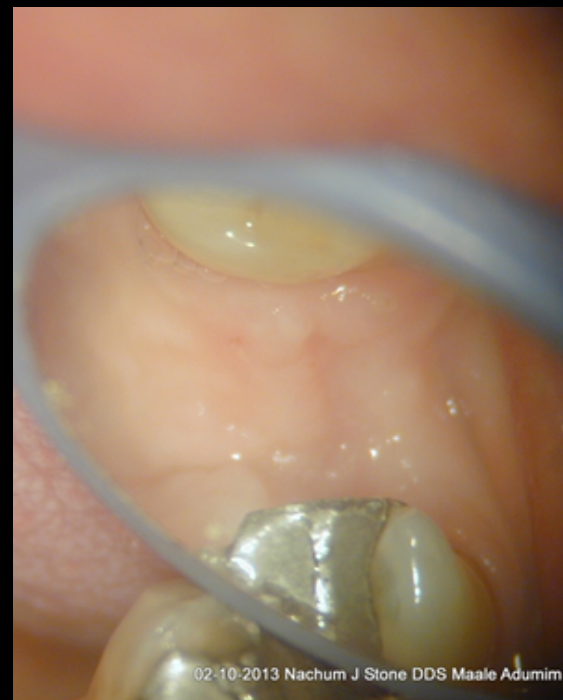



16 weeks post op
Implant in place(fig6)



16 weeks post op
Hard tissue appearance(fig5)



16 weeks post op
Soft tissue appearance (fig4)

Case #3

Patient: 72 years old female

In this case, a large bone deficiency remains after that hopeless teeth 35,36 37 38 were removed. The treatment decision was to augment in the first stage and implants will be placed in the second stage.

Teeth were extracted and augmentation was carried out by using Bond Apatite® as a graft material. Tenting screws and protective rigid external dressing was applied above the graft. In day 1 of the graft application it appears entirely radio opaque on the X-ray image. (Fig. 2)

4 weeks post op, a defuse radiolucency spots can be distinguished on the radiography (Fig. 3) as well on the 6 weeks post op, when the external protective shield was removed (Fig. 4).

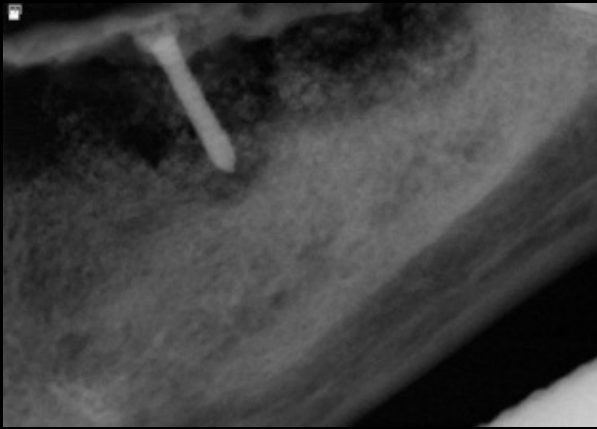
This image is seen because the biphasic calcium sulfate matrix is progressively and completely degraded and replaced by new osteoid formation. The osteoid in this stage is un calcified, hence it appears radiolucent. However, gradually re-calcification of the osteoid is taking place and in the radiography radio opacity take place (Fig. 5).

Healing went uneventfully .

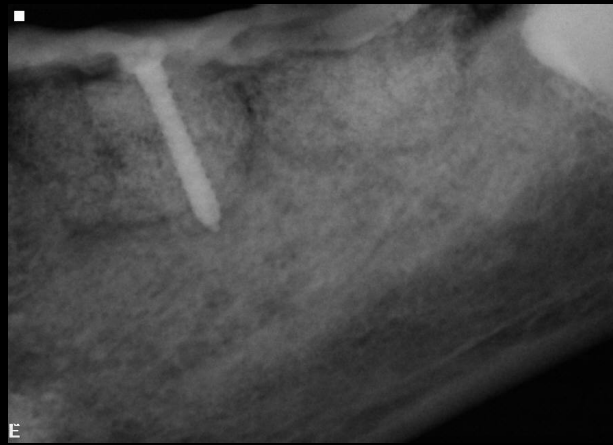Radiographic images:

- (Fig. 1) Pre op situation, before extraction.*
- (Fig. 2) On day one teeth were extracted and Bond Apatite® in place covered by external shield supported by tenting screw.*
- (Figs. 3,4) 4 and 6 weeks post op defuse radiolucency can bee seen.*
- (Fig. 5) Re-calcification of the new formed osteoid.*
- (Fig. 6) Pre op CT scan image.*
- (Fig. 7) Post op CT scan image demonstrates the new formed bone already in 14 weeks post op .*

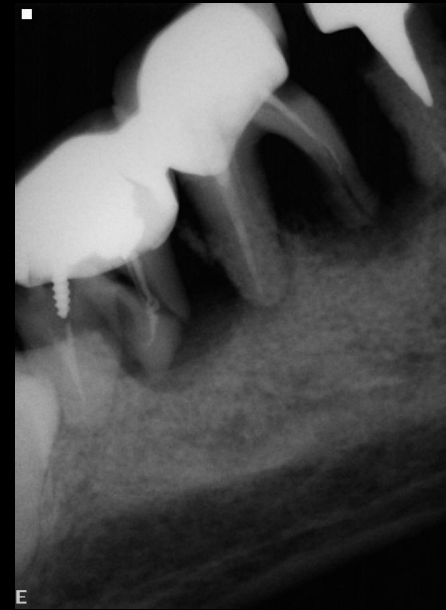As opposed to single component graft, when the new formed bone is minimal and limited into the gaps in-between the granules, the combination of the composite graft with the calcium sulfate increases dramatically the amount of the new vital bone formation due to the replacement of the CS matrix



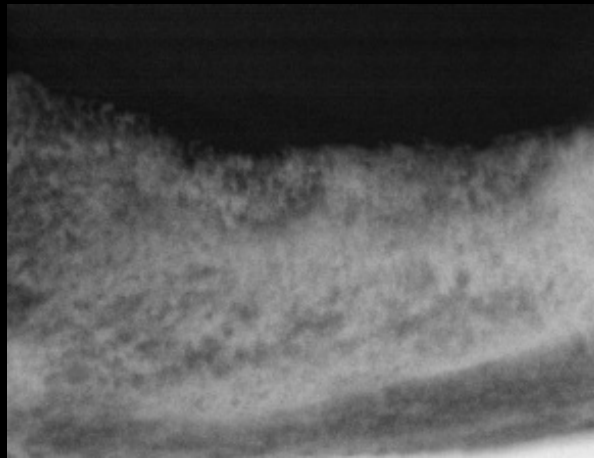
4 weeks post op (Fig. 3)




Bond apatite® in place on day 1
A protective external composite shield
is used supported by tenting screws (Fig. 2)



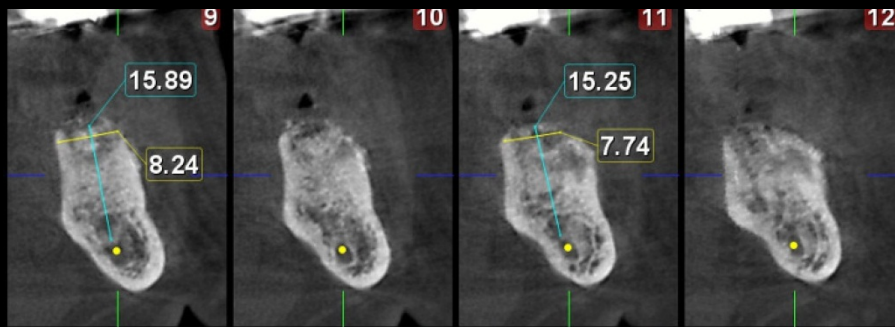
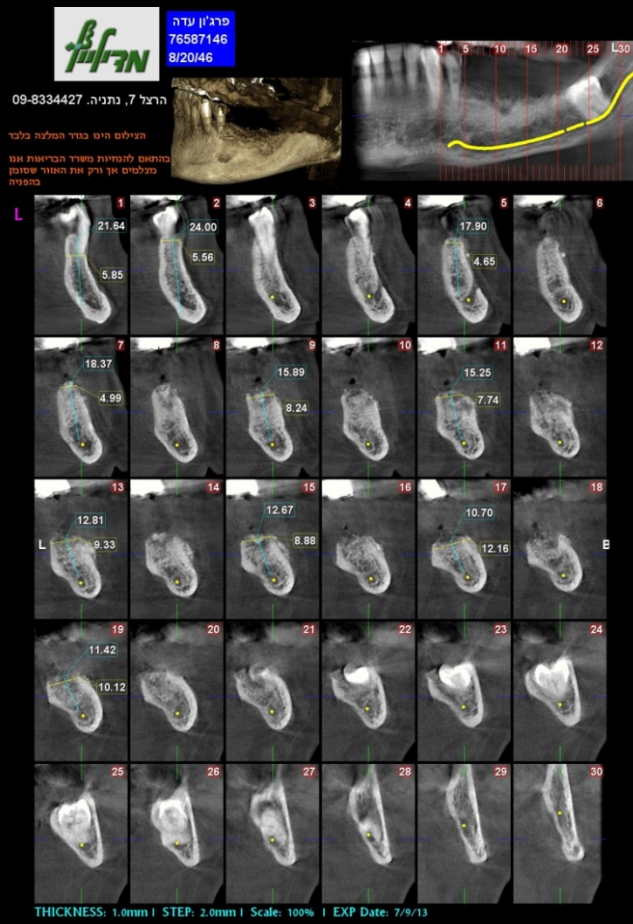
Pre op radiography (Fig. 1)



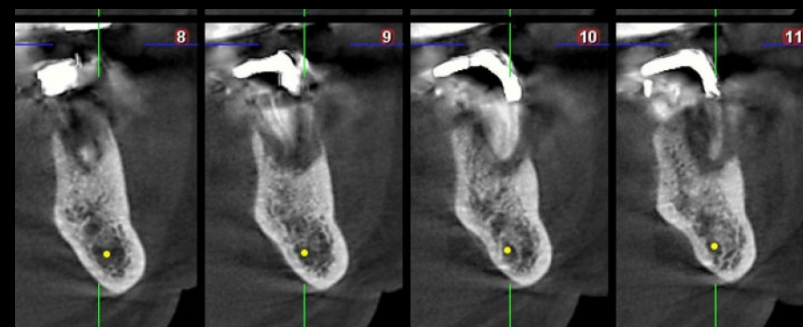
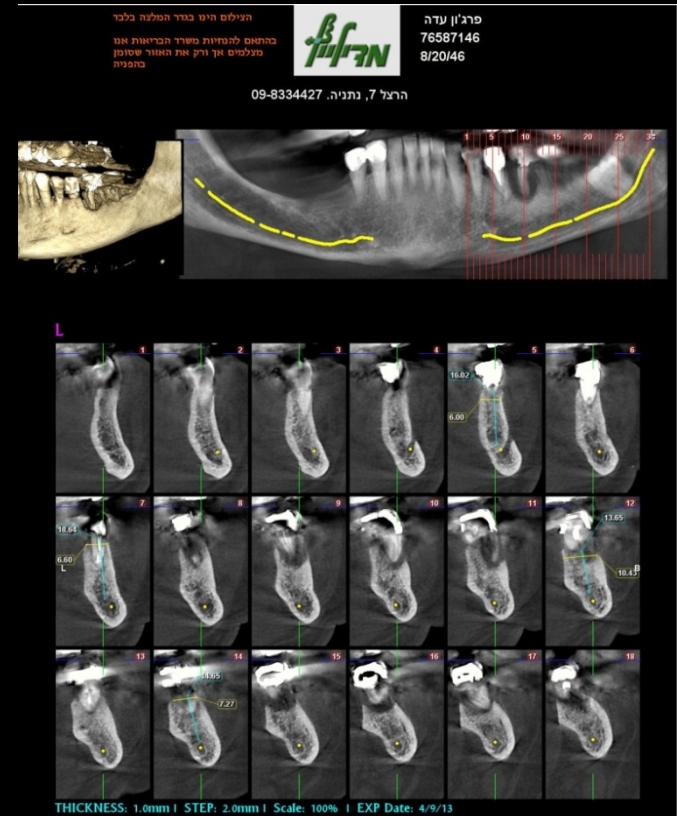
14 weeks post op re-calcification and
gradual maturation
of the new formed bone (Fig. 5)



6 weeks post op, the external protective
shield has been removed (Fig. 4)



Post op appearance on the CT scan
After 14 weeks from day 1(Fig. 7)



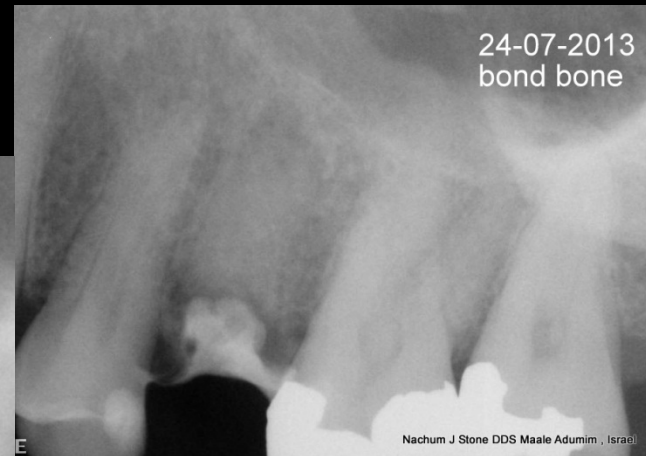Pre op appearance on the CT scan (Fig. 6)

Consecutive radiographic appearance illustrates the Biphasic calcium sulfate (BondBone[®], 3Dbond .) transformation into new formed bone

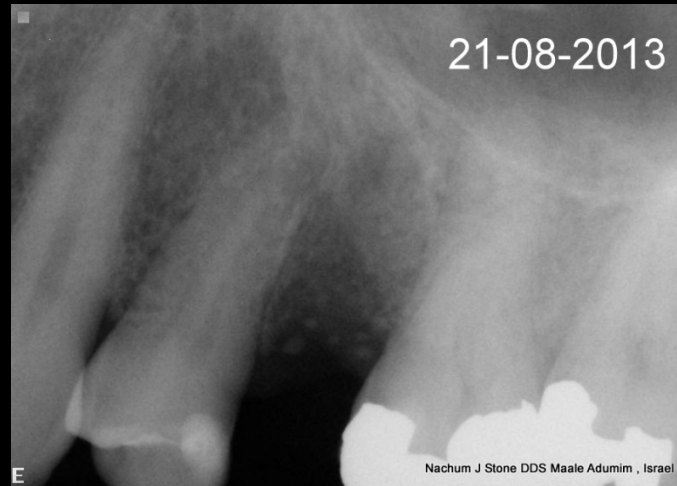The following x rays images illustrate the radiographic appearances during the healing phases of the bone formation in the grafted area when using as a graft material the biphasic calcium sulfate (BondBone[®]) by itself .

Due to the graft nature, the graft is completely degraded and replaced by new bone formation

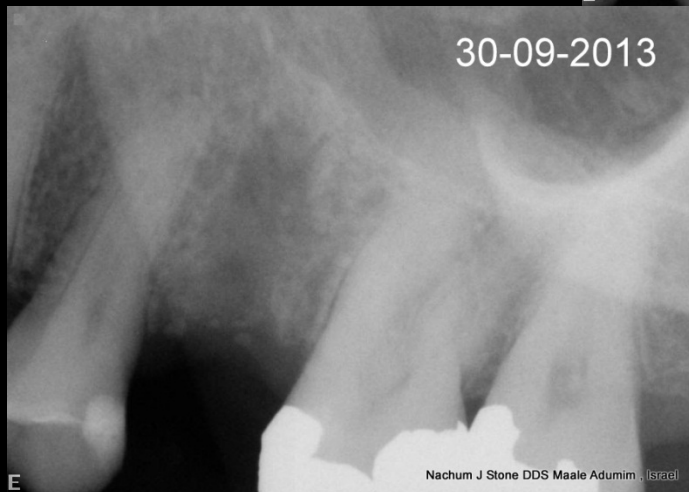- (Fig. 1) Radiograph image immediately after graft placement
(the material appear radio opaque)*
- (Fig. 2) 4 weeks post op, the grafted area looks as a complete disappearance of graft has occurred all the defect area has a radiolucent aspect.
(at this stage the calcium sulfate was degraded and replaced by new uncalcified osteoid)
The clinician might think that the graft was lost.*
- (Fig. 3) 8 weeks post op, gradual calcification of the osteoid can be seen in the grafted area
by the radiography the image appear more radio opaque with similar trabecular pattern as the surrounding native bone .*



(Fig. 1)

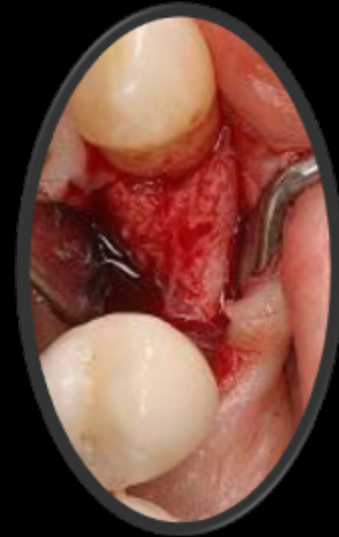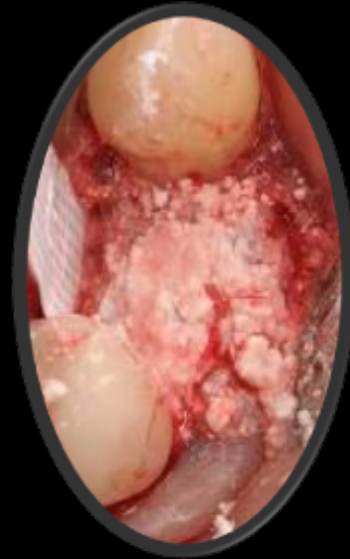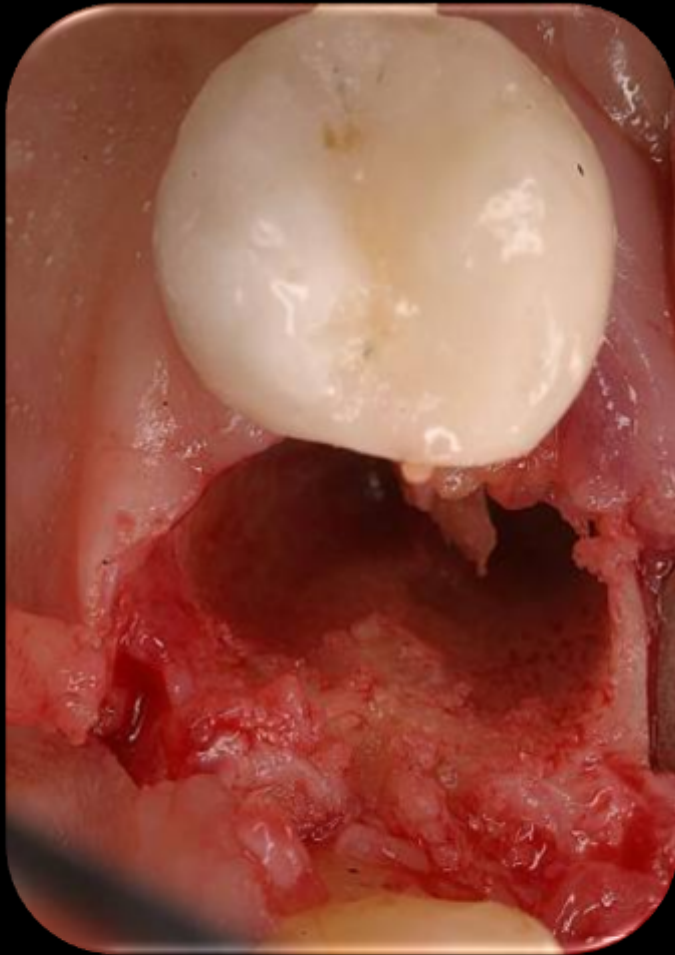


(Fig. 2)



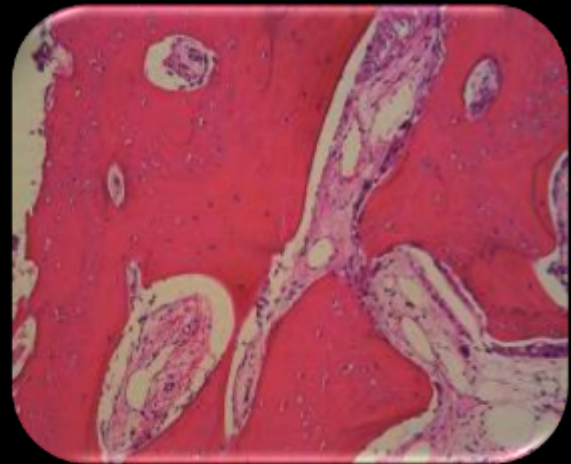
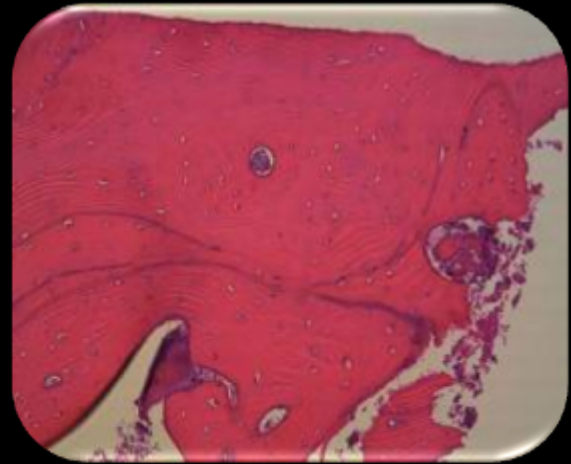
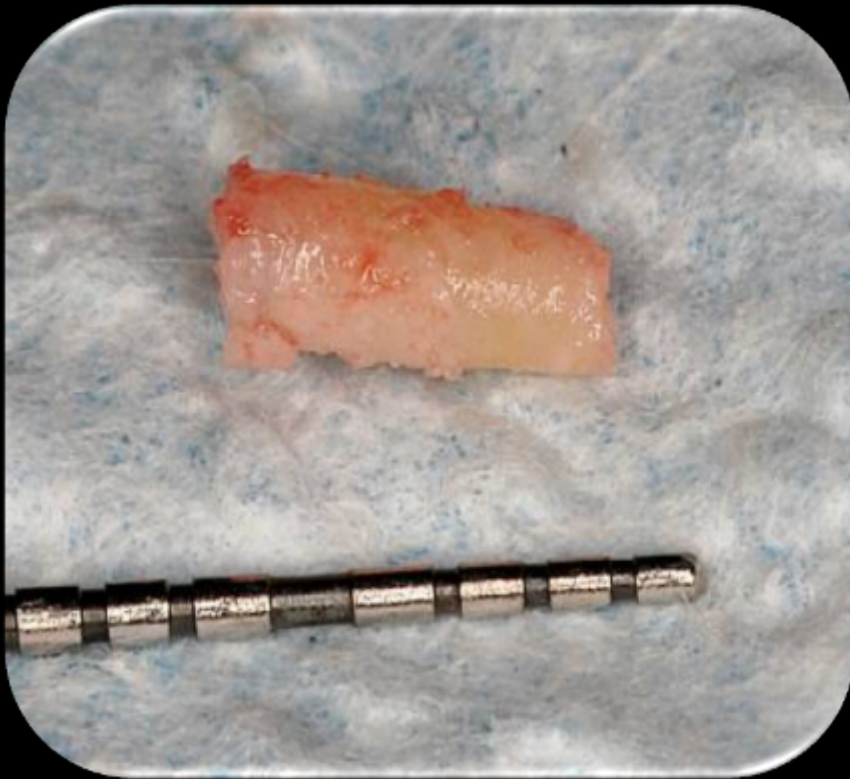(Fig. 3)

Socket preservation



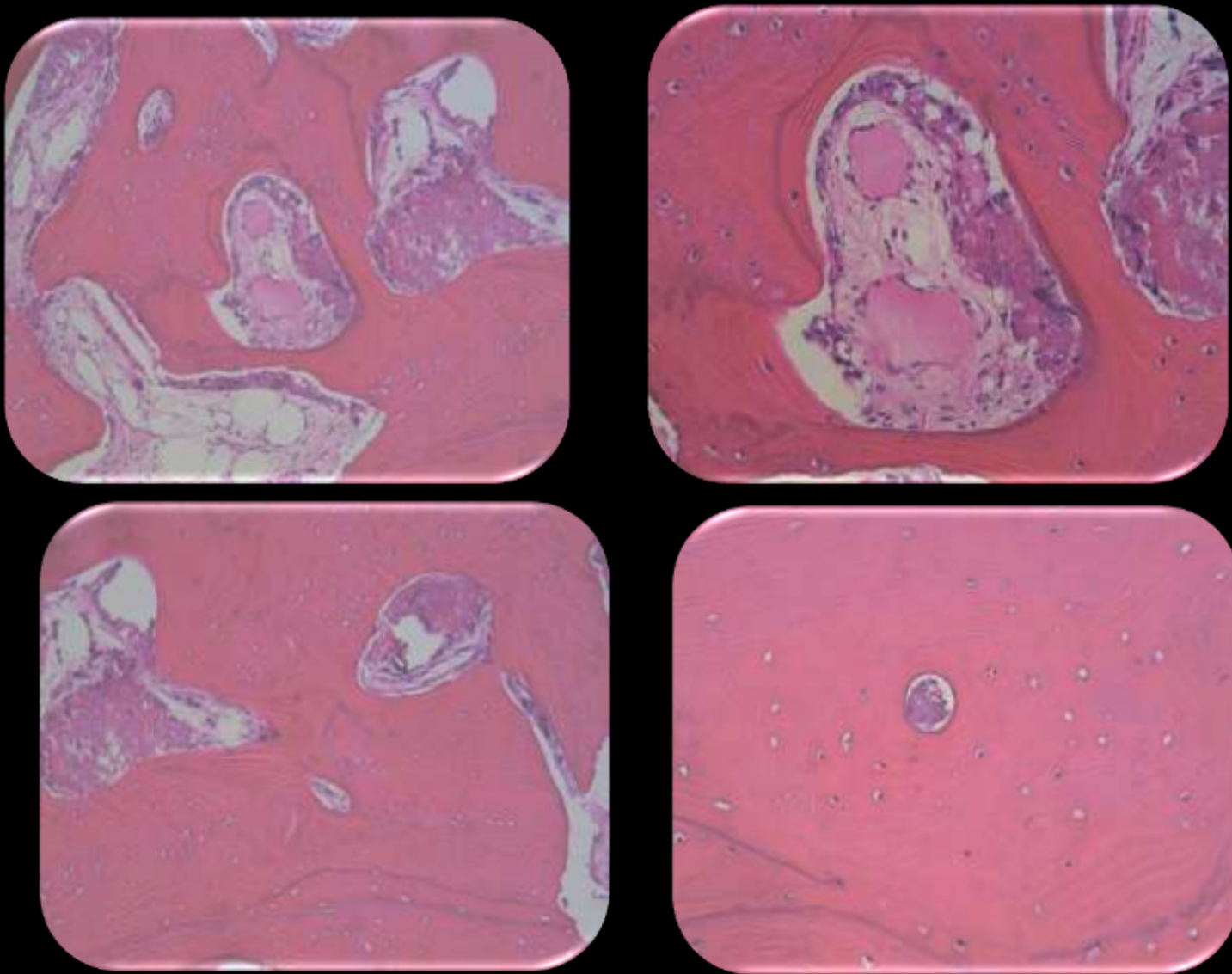
Surgery was performed by Dr. Robert A. Horowitz, DDS (USA)

Histologic evaluation of biphasic calcium sulfate



Surgery was performed by Dr. Robert A. Horowitz, DDS (USA)

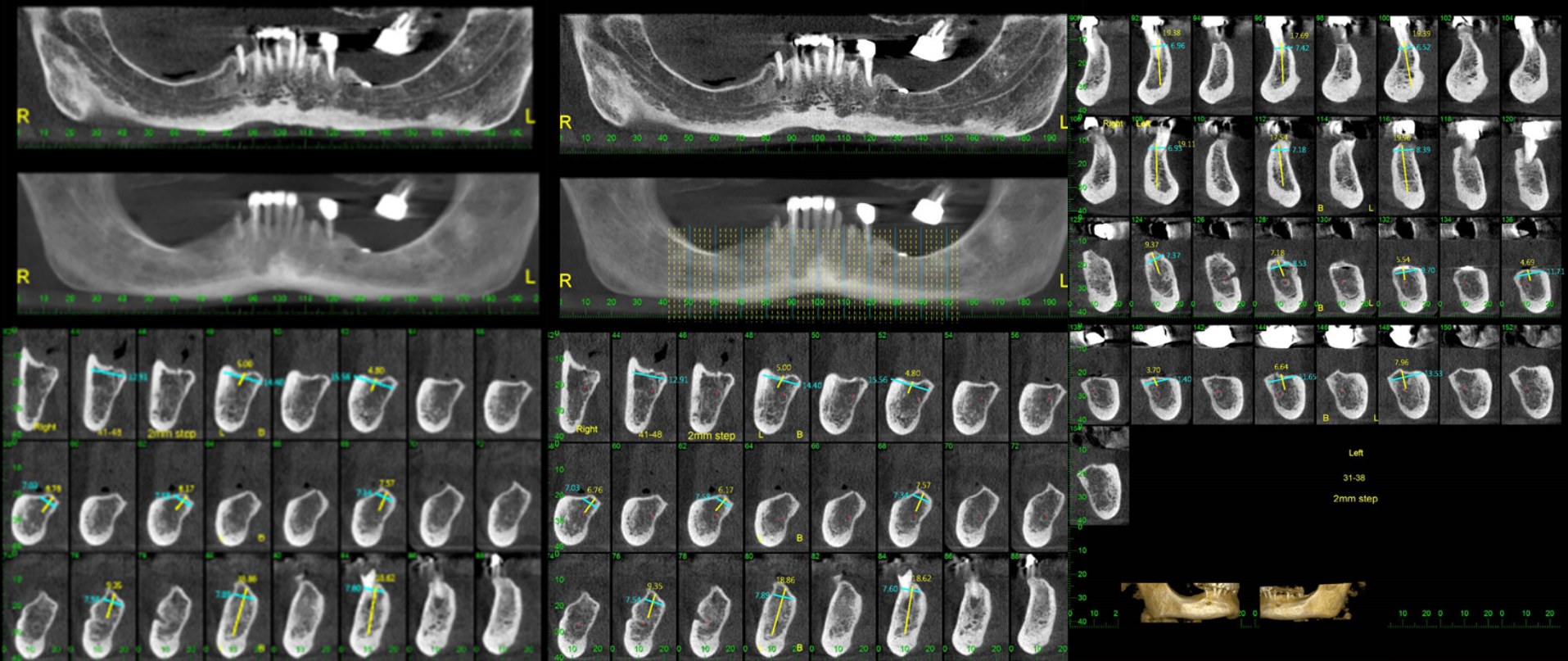
Histologic evaluation of biphasic calcium sulfate



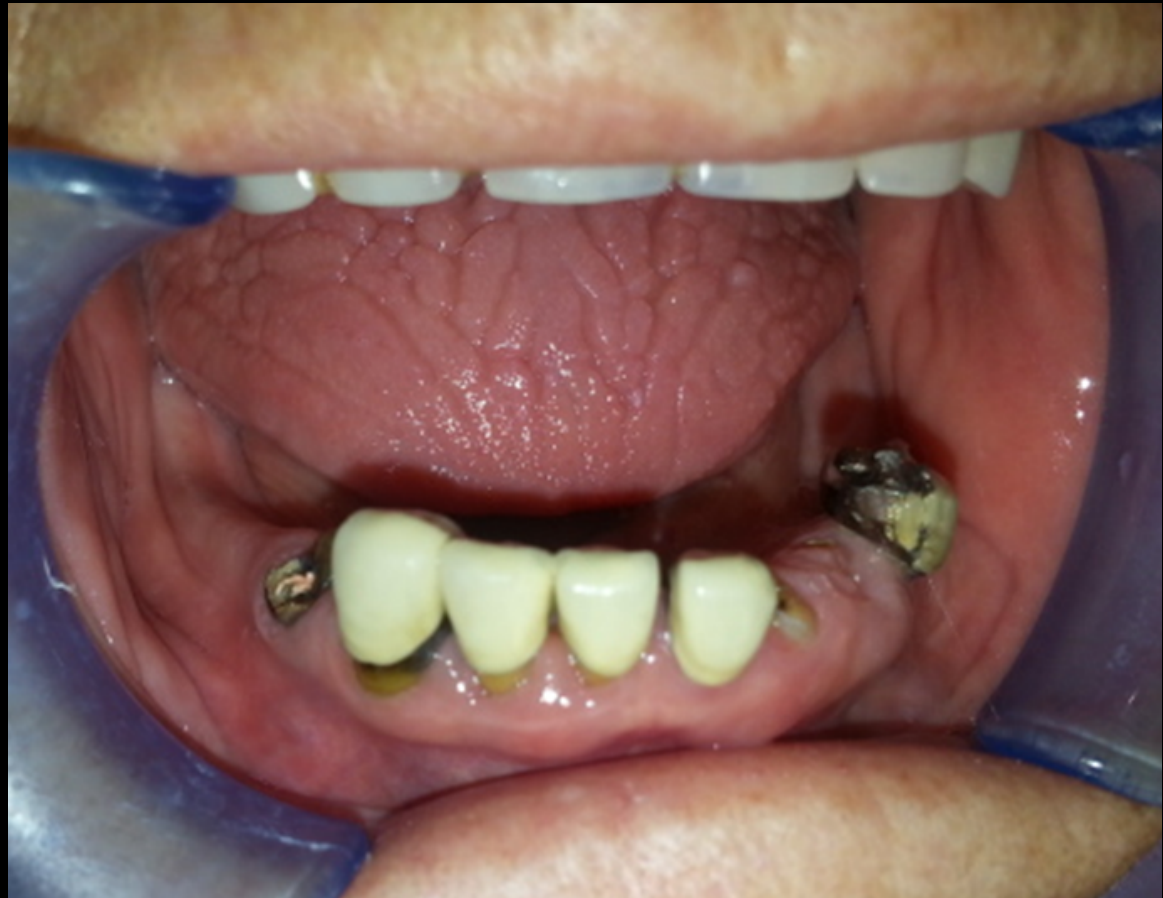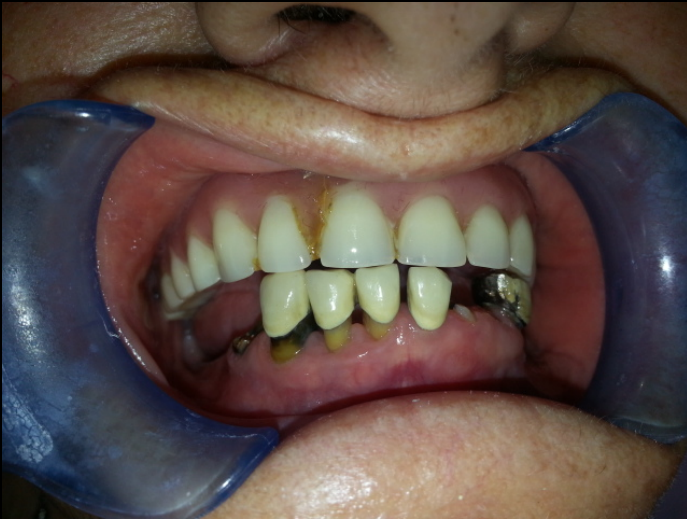Histology was performed by Robert A. Horowitz, DDS

- *A 72 year old female*
- *General condition : non smoker*
- *diabetes tip 2*
- *high blood pressure*
- *Drags : Aspirin*
- *Cardilog*
-
- *Present a perio teeth situation- lower jaw*
- *Old PFM crowns- lower jaw*
-
- *Upper jaw – full over denture*

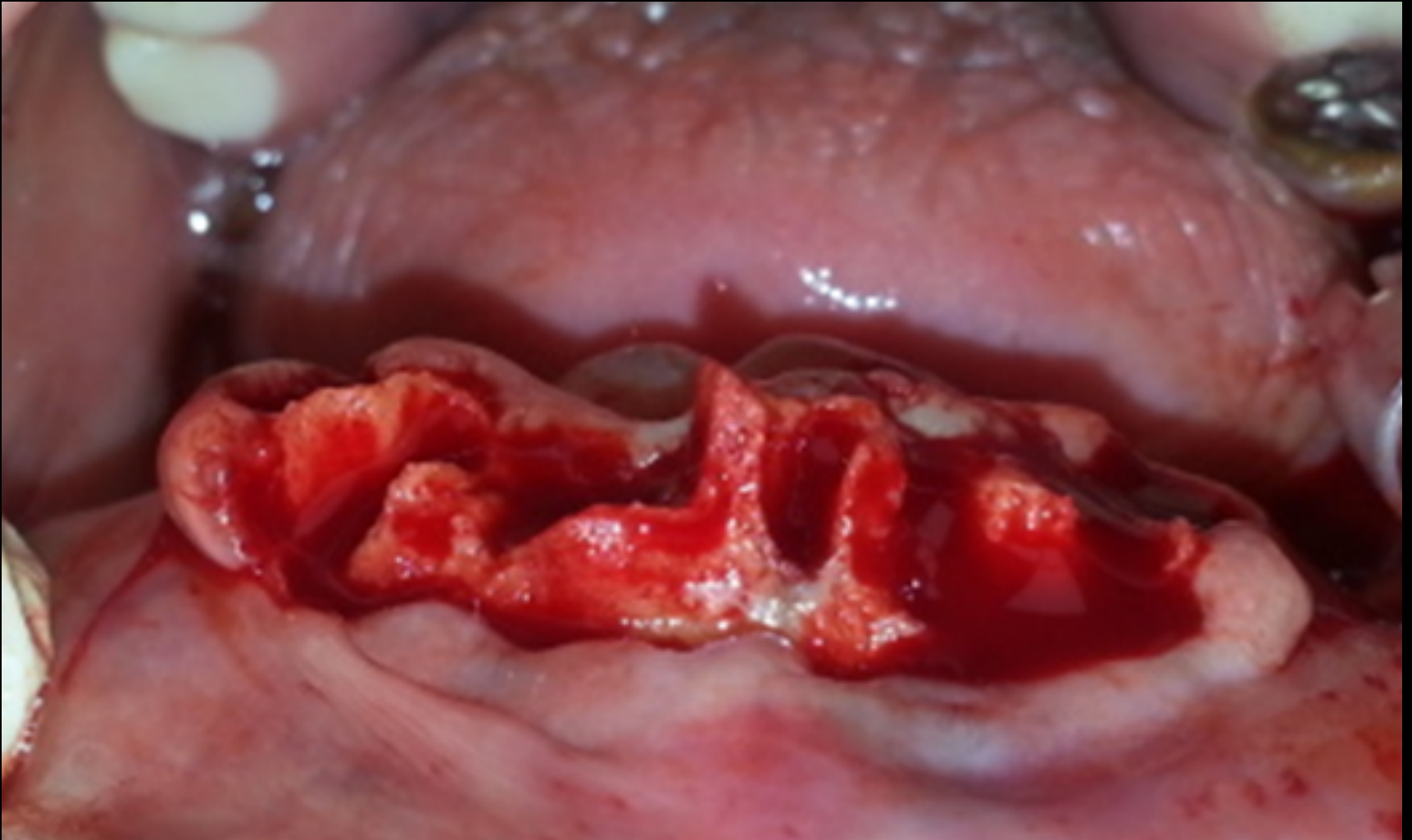
*Con-beam computed tomography
taken at the initial consultation*



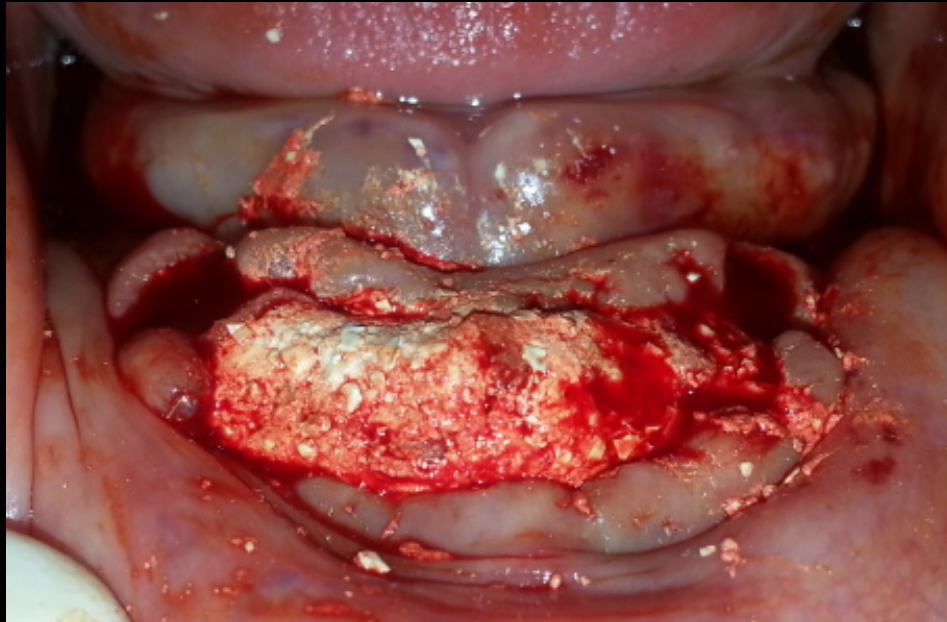
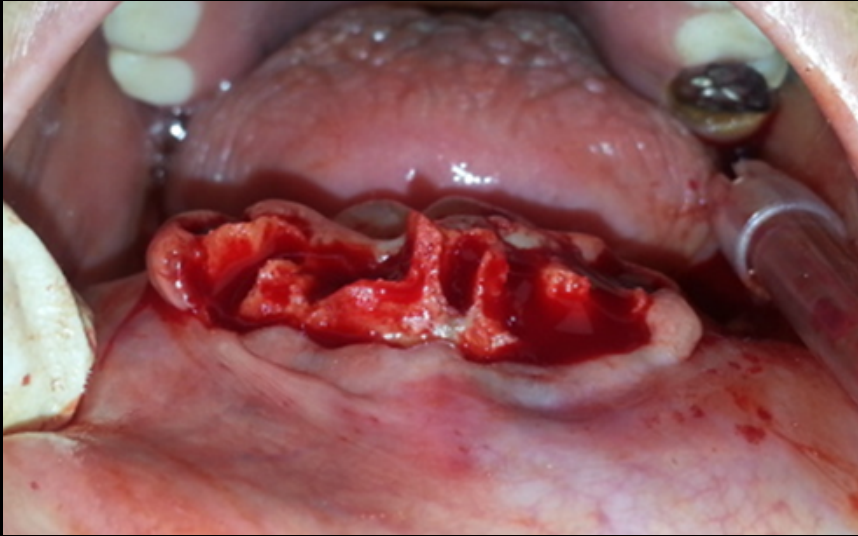
Preoperative condition of existing teeth



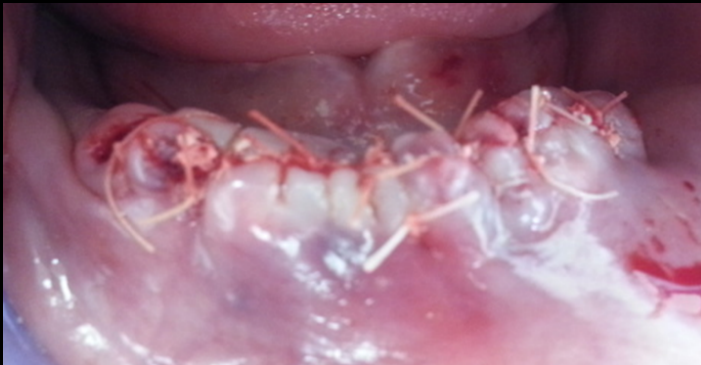*Extraction of all teeth
a deformed and irregular crest can be seen*



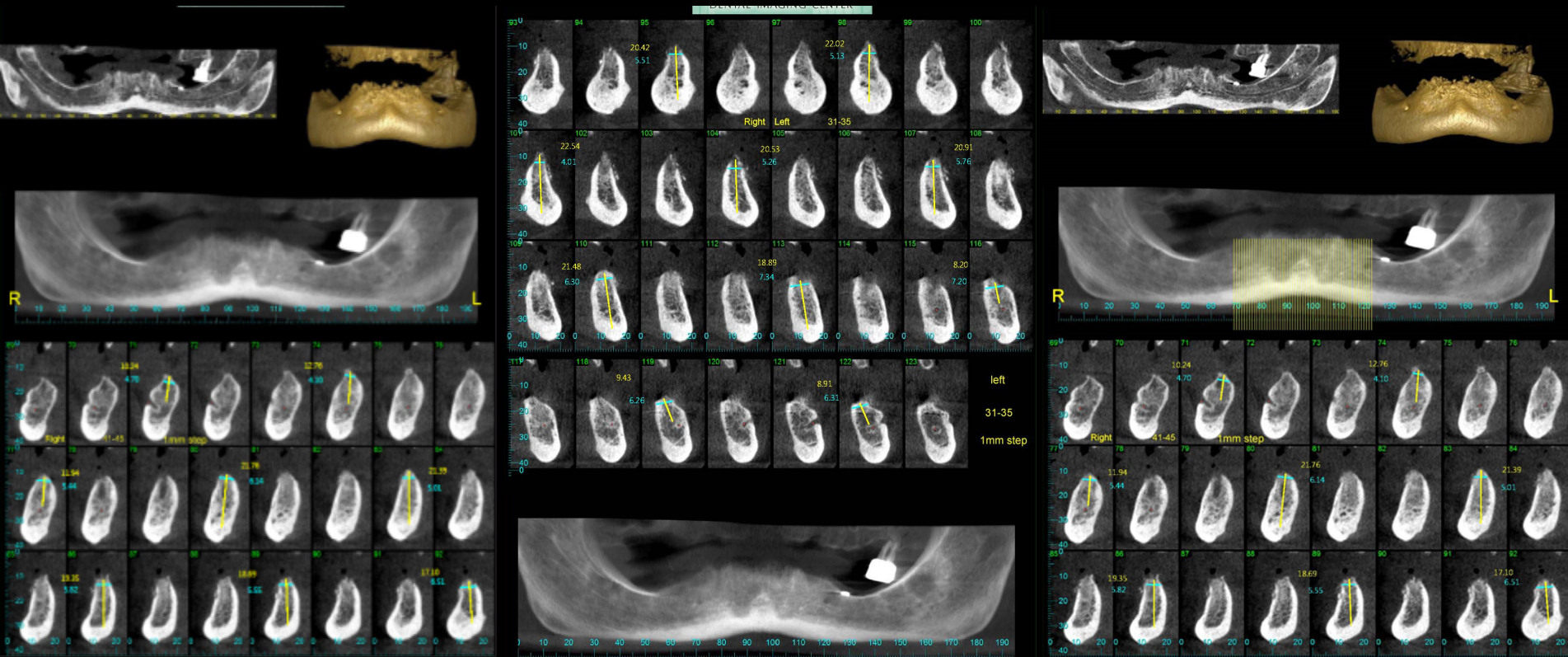
*Application of Bond apatite®
Augma-biomaterials™
bone substitute*



primary closure with vicryl sutures 4/00

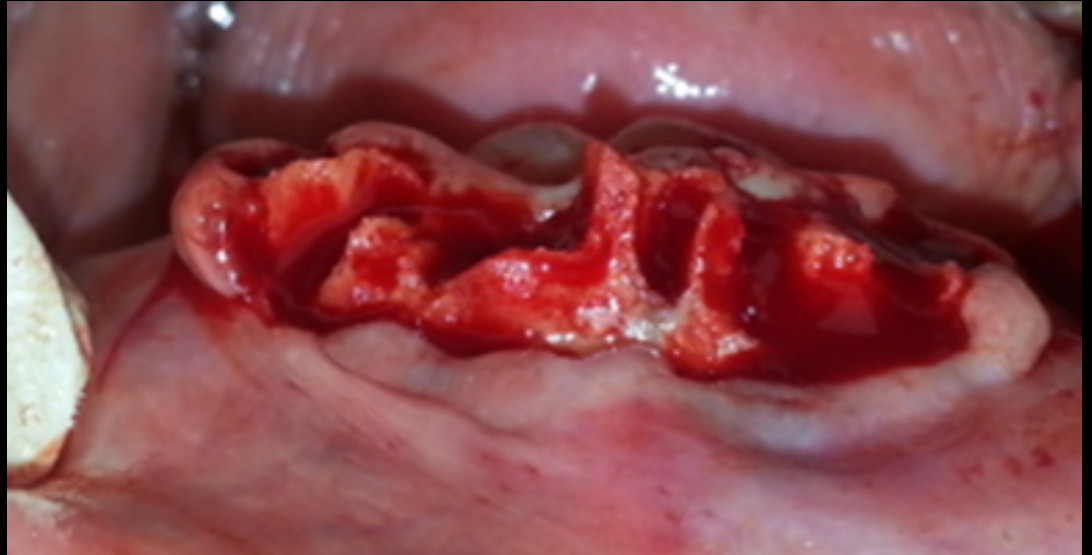

CBCT 4.5m AFTER EXTRATION AND “Bond apatite ®” APPLICATION

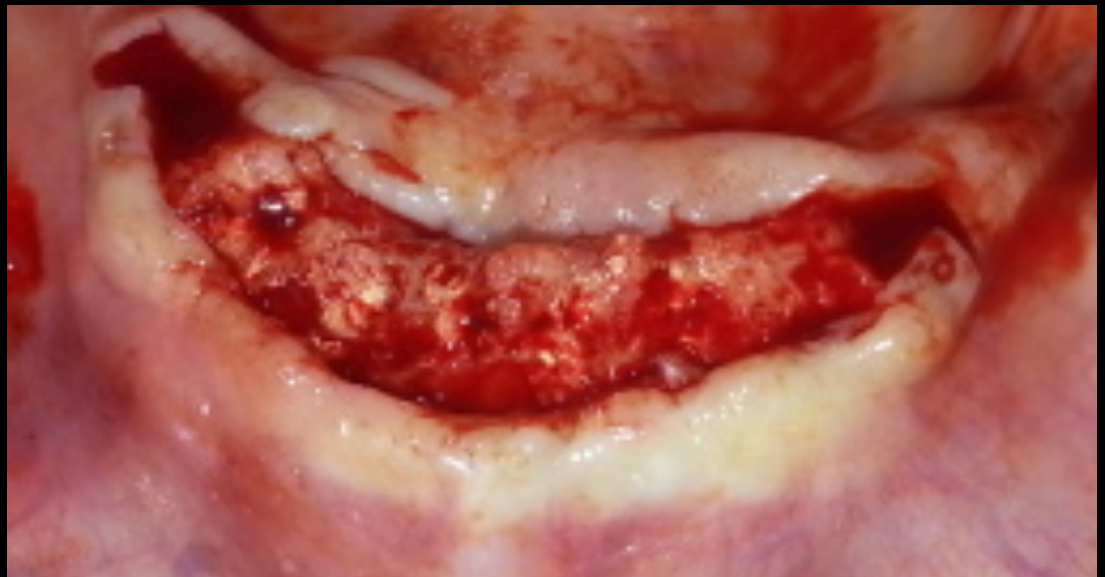

Homogenous crest formation

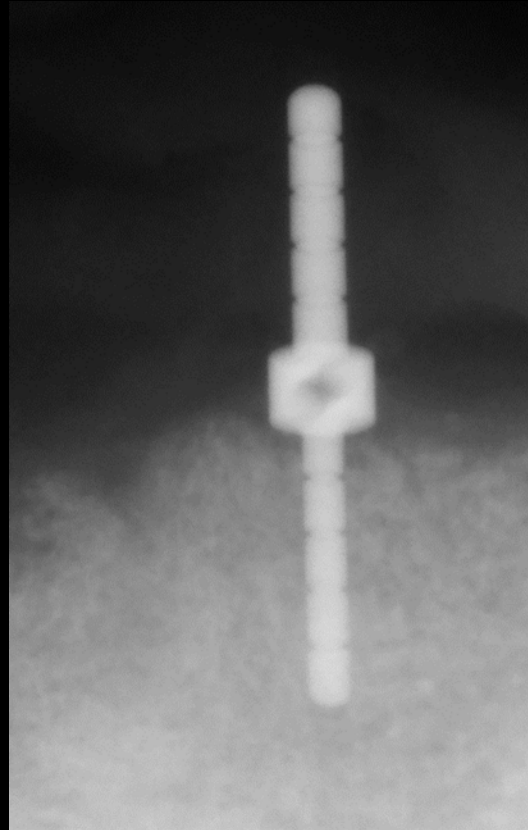
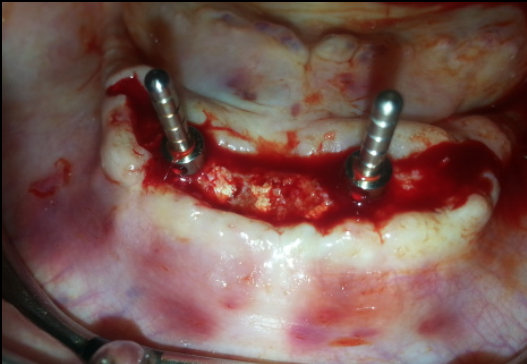
Before



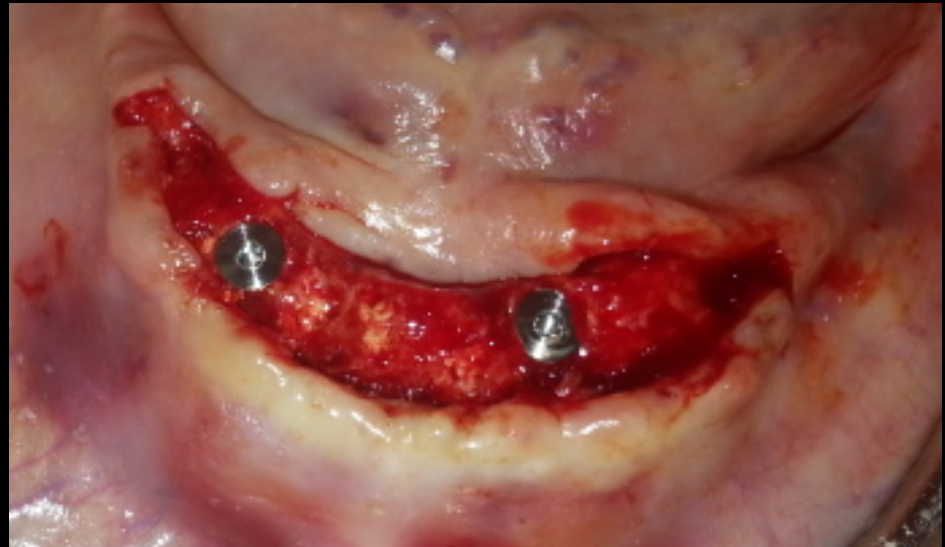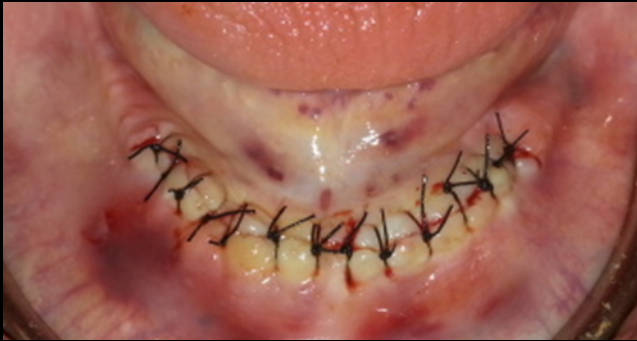After



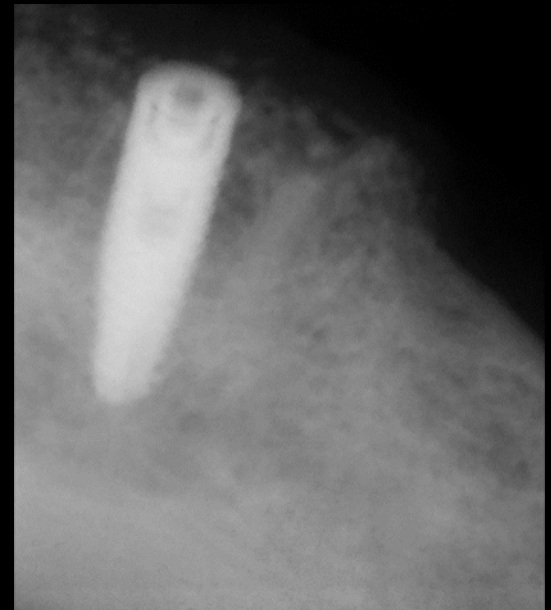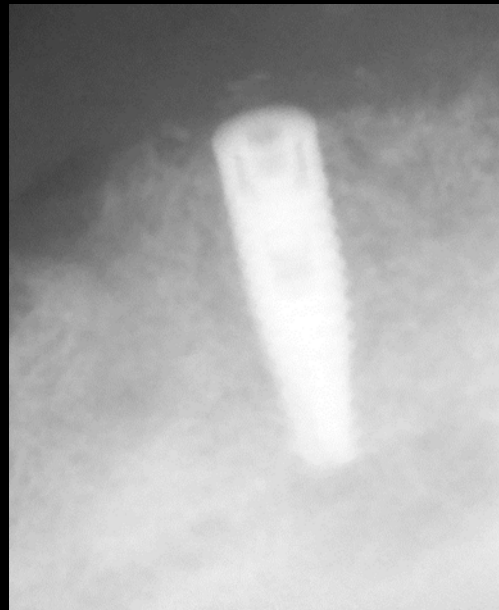
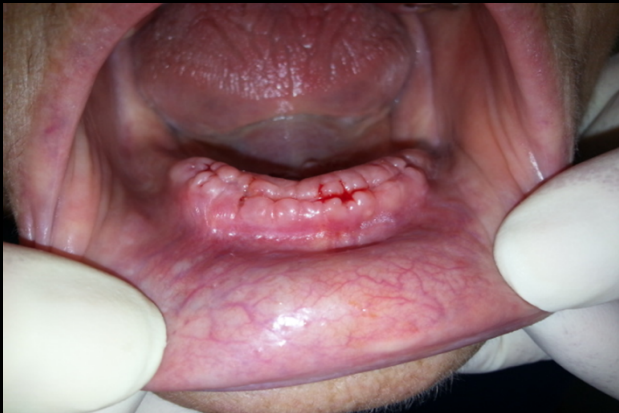Initial parallel pins established the location for the osteotomies



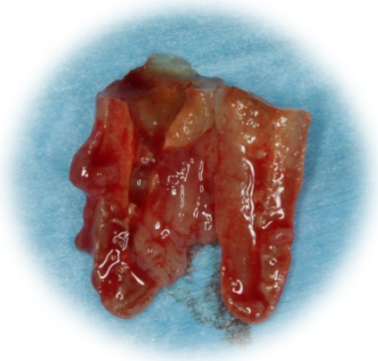
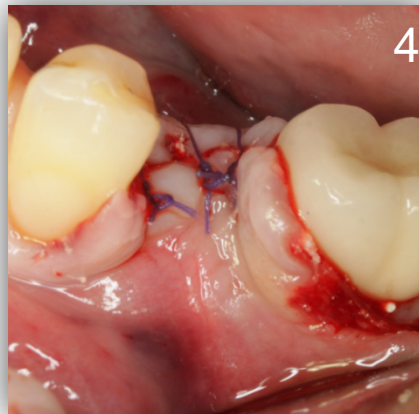
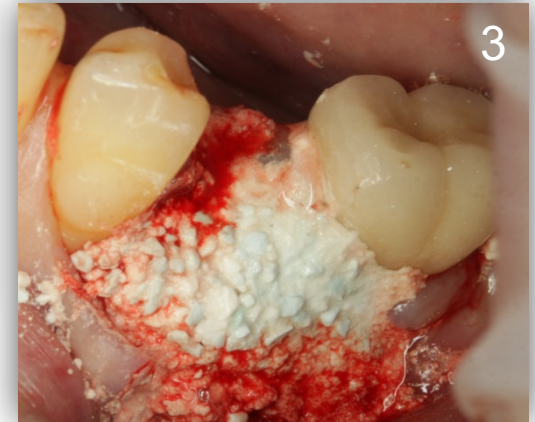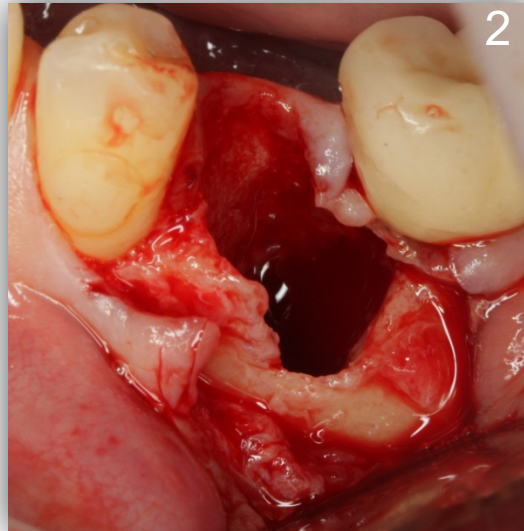
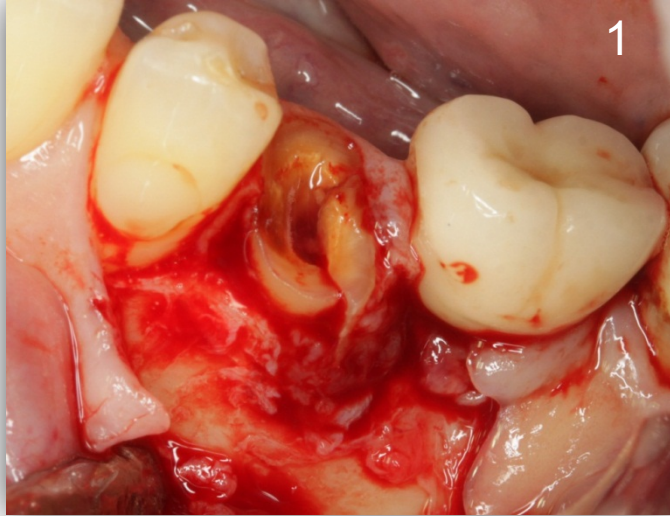

Implants insertion (Paltop advanced 3.75 / 13)



One week after implants insertion



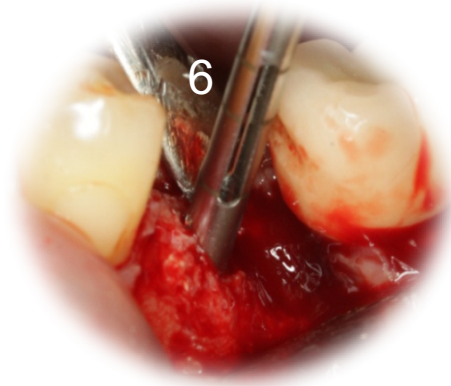
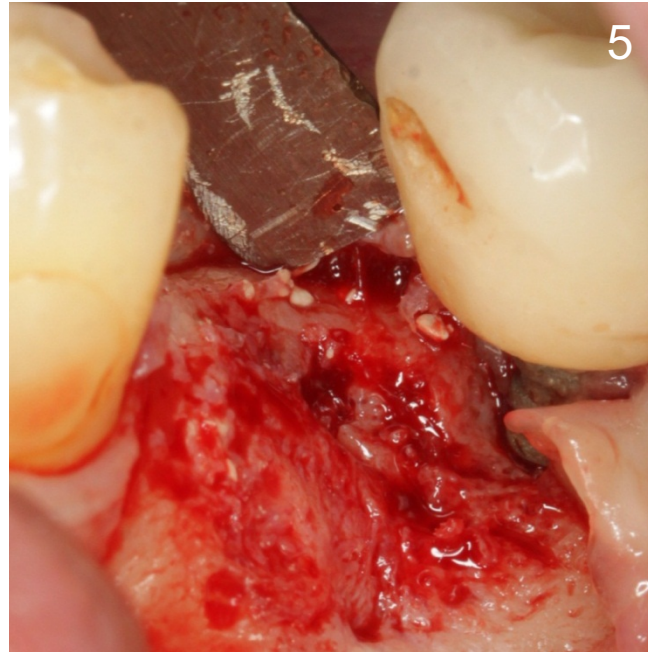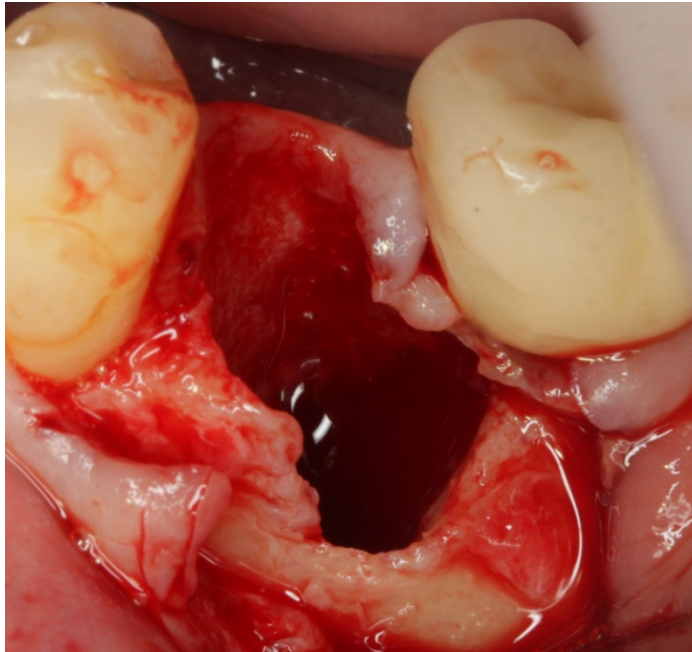

Augmentation post root fracture using Bond Apatite®

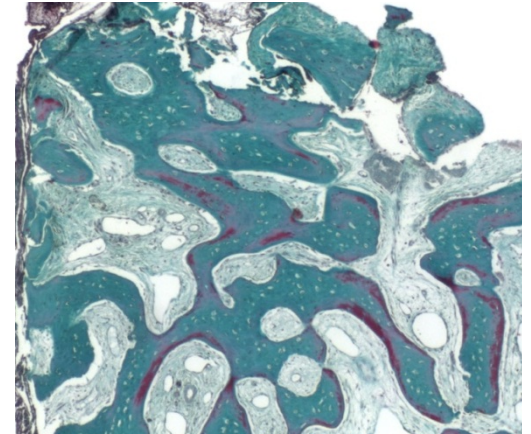
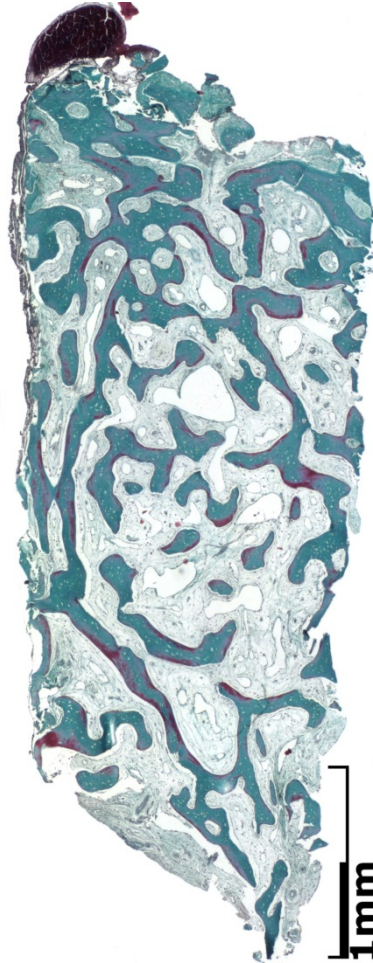
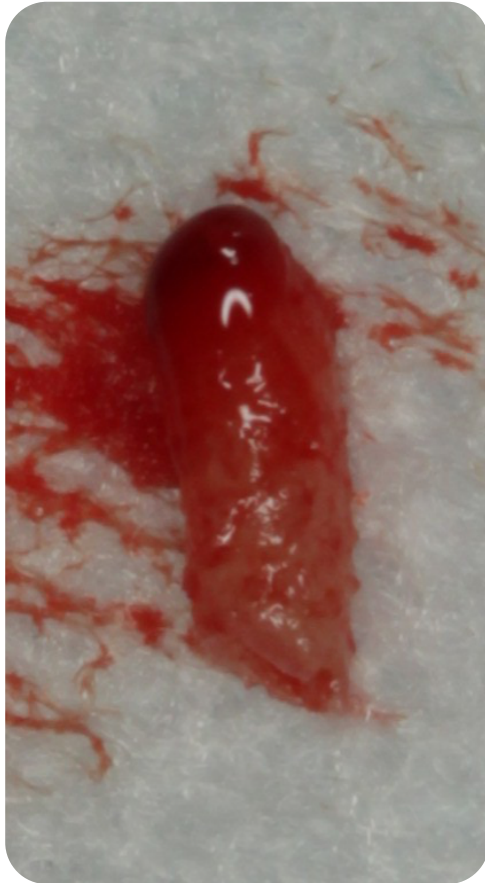


Bond Apatite®
Bone Graft Cement

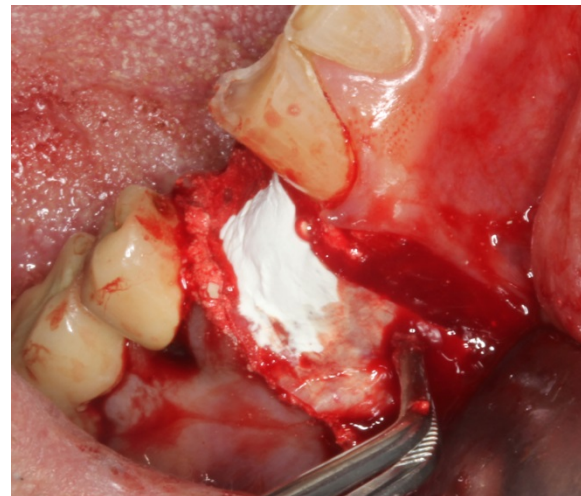
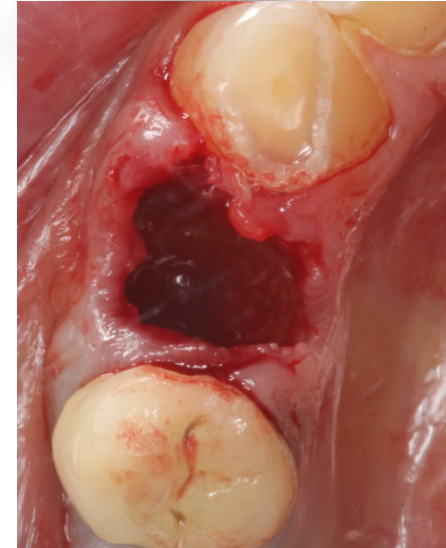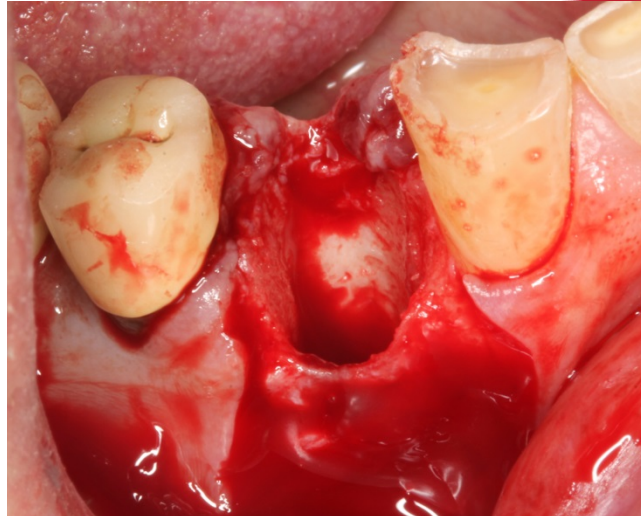
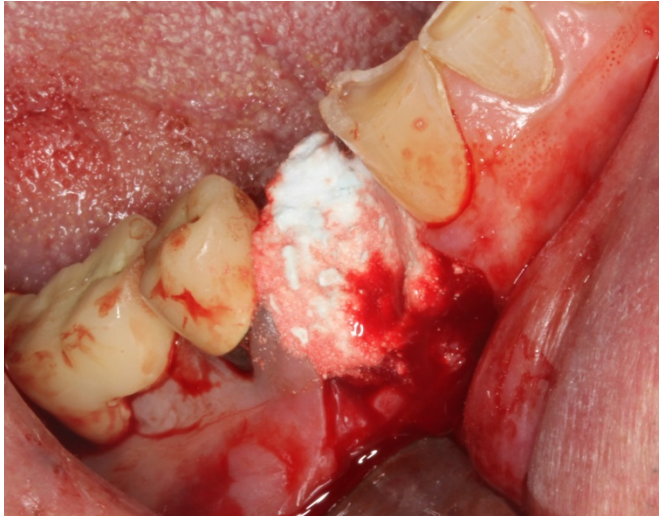


Augma
BIOMATERIALS

3 month post op





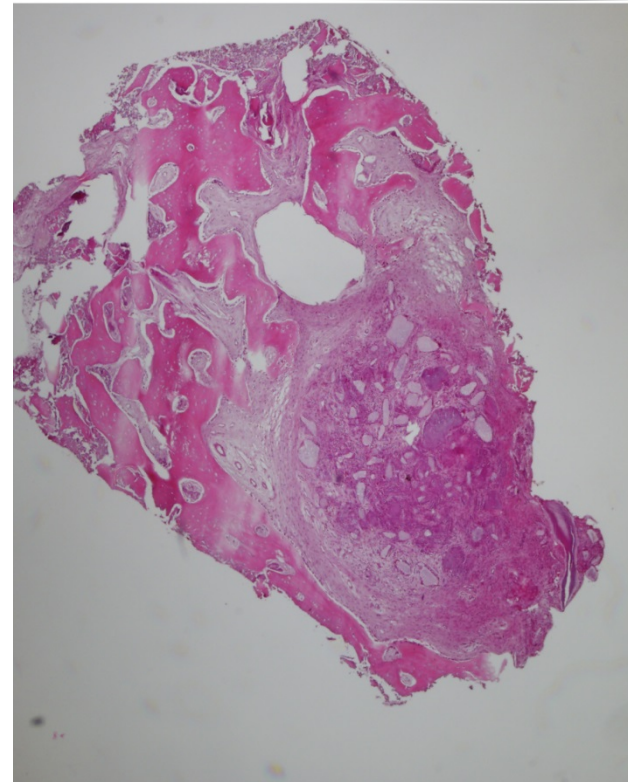
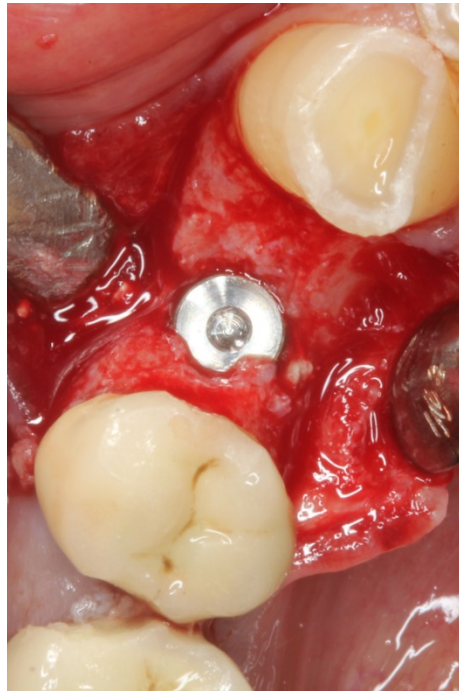
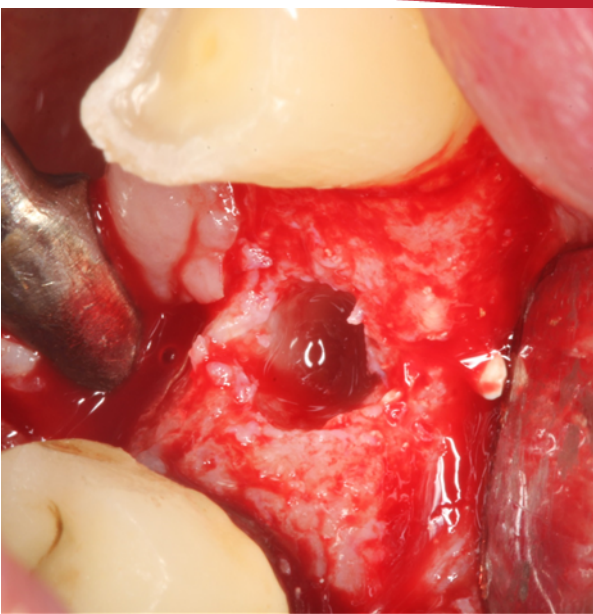Socket preservation using Bond Apatite[®]



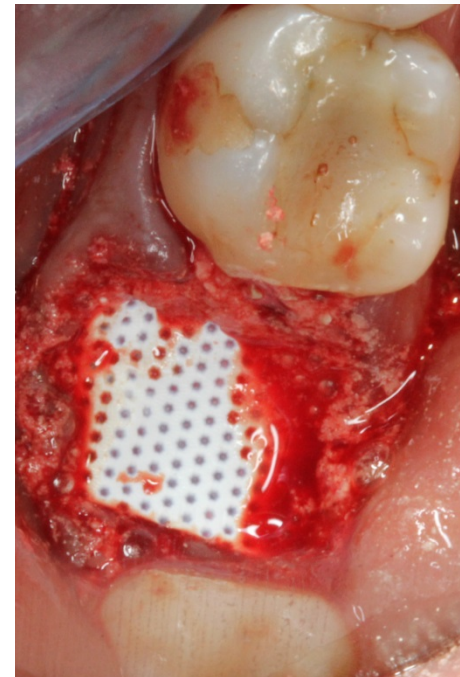
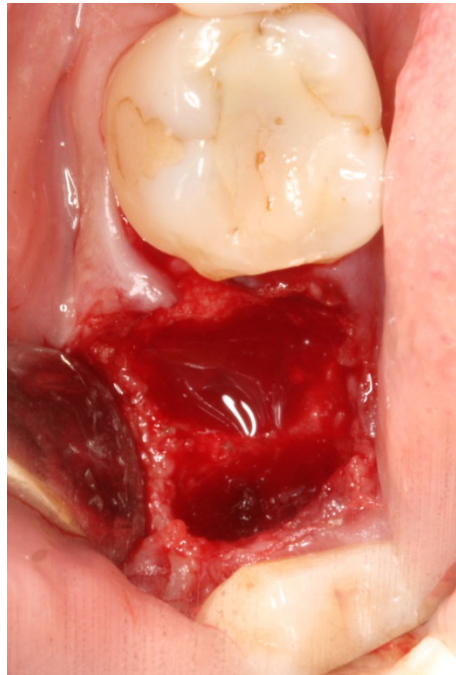
Bone Graft Cement

Surgery professor Ziv Mazor ,DMD Israel

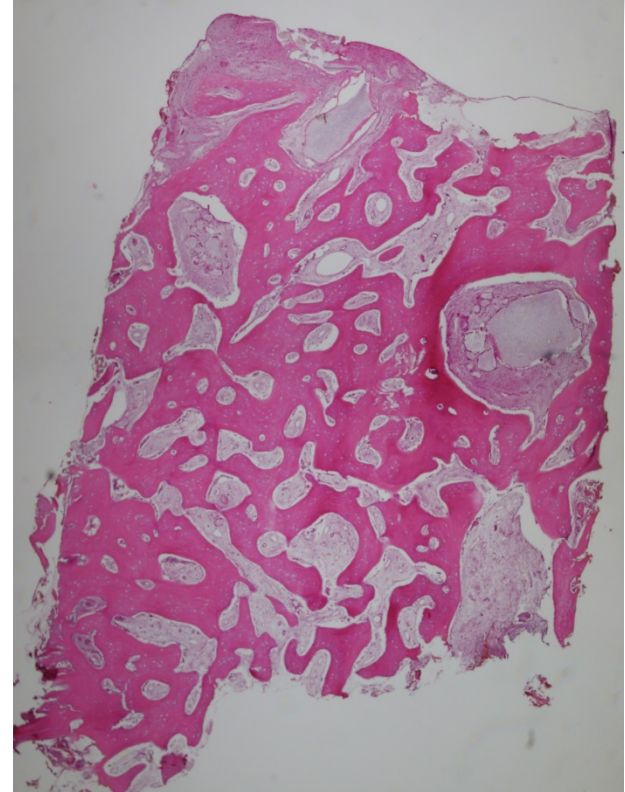
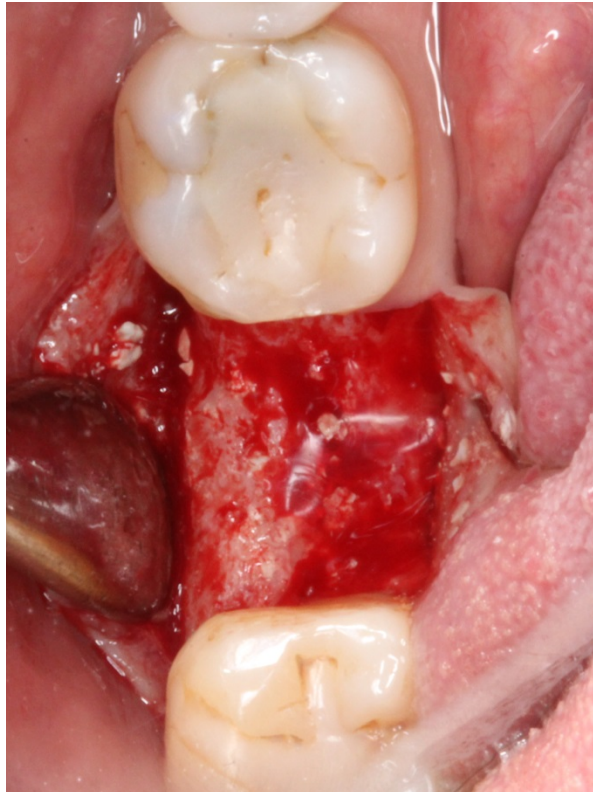
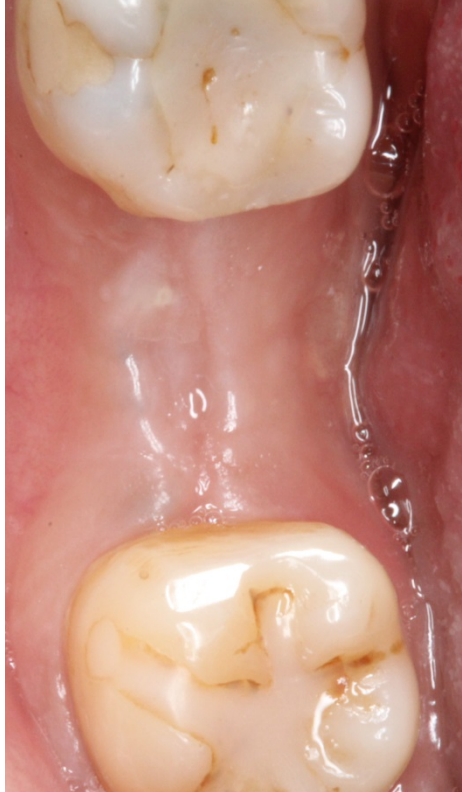3 months post op implant was placed and
core was taken foe histologic evaluation

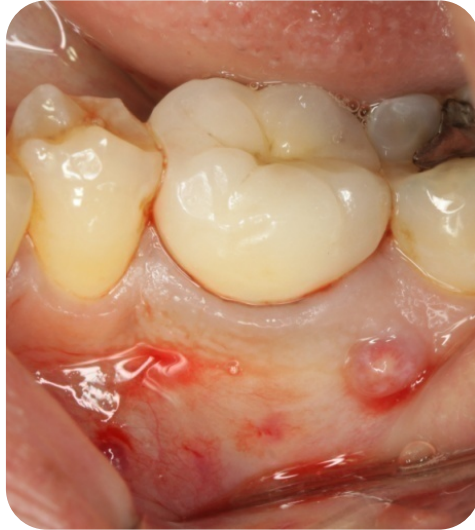


Socket preservation using Bond Apatite® temporarily covered by PTFE membrane

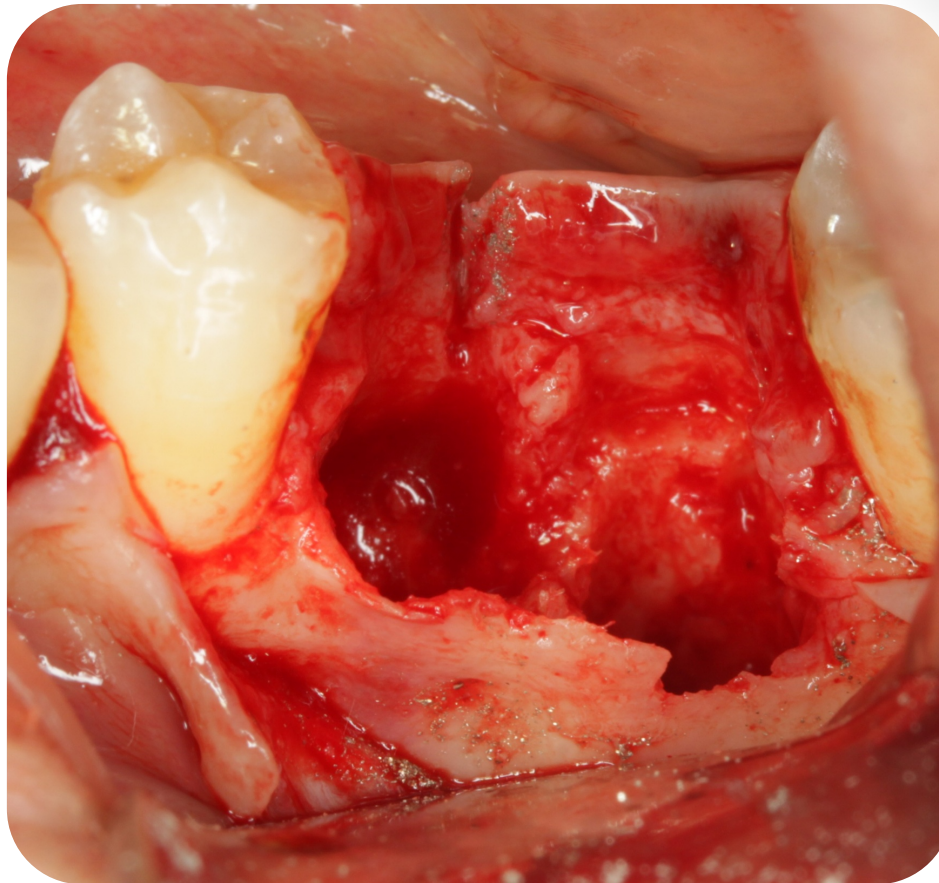


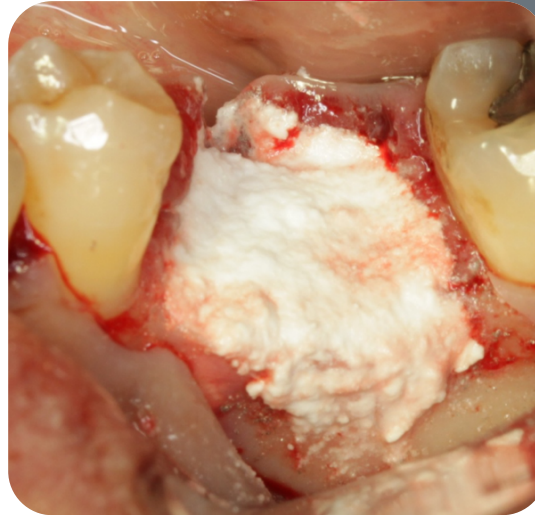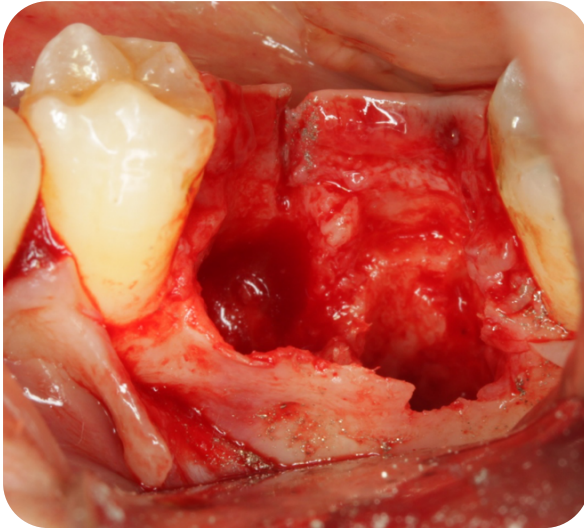
Clinical and histologic appearance 3 months post op



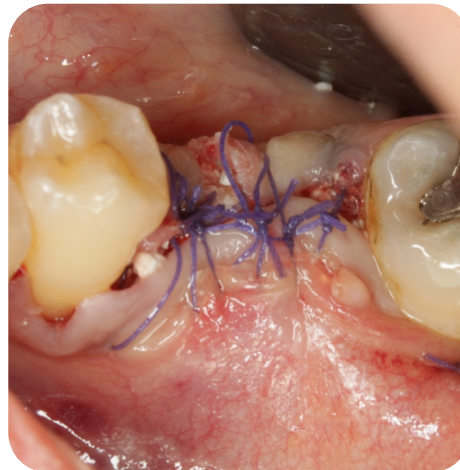
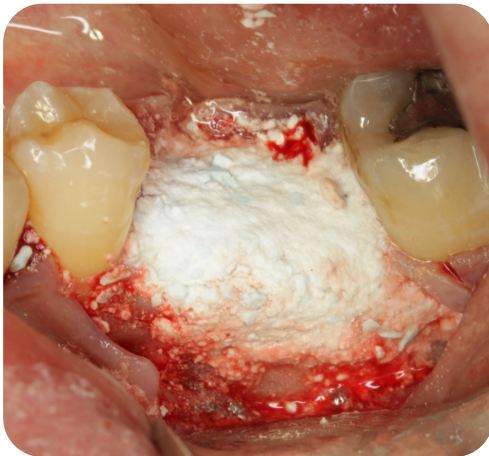
Large bone defect post hopeless tooth extraction



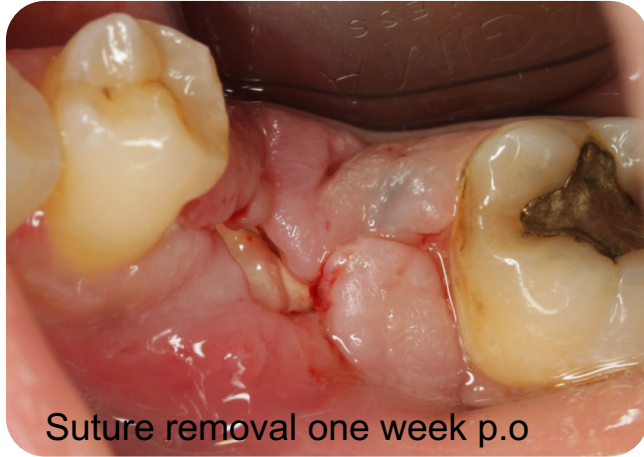

Bond apatite in place

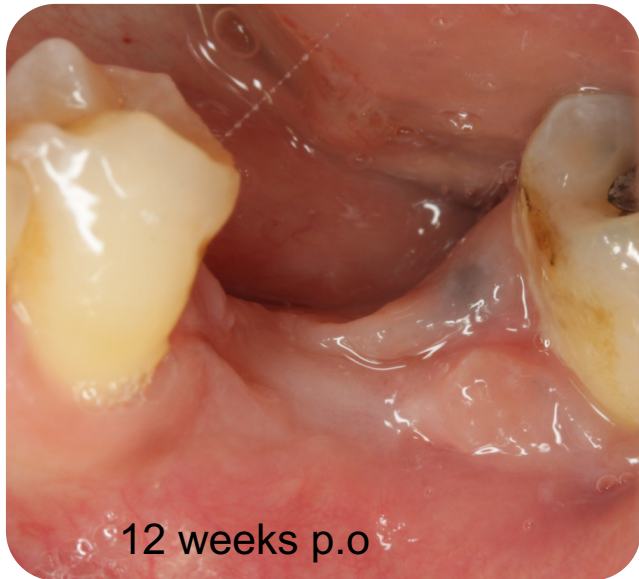

Bond Apatite®
Bone Graft Cement


Augma
BIOMATERIALS

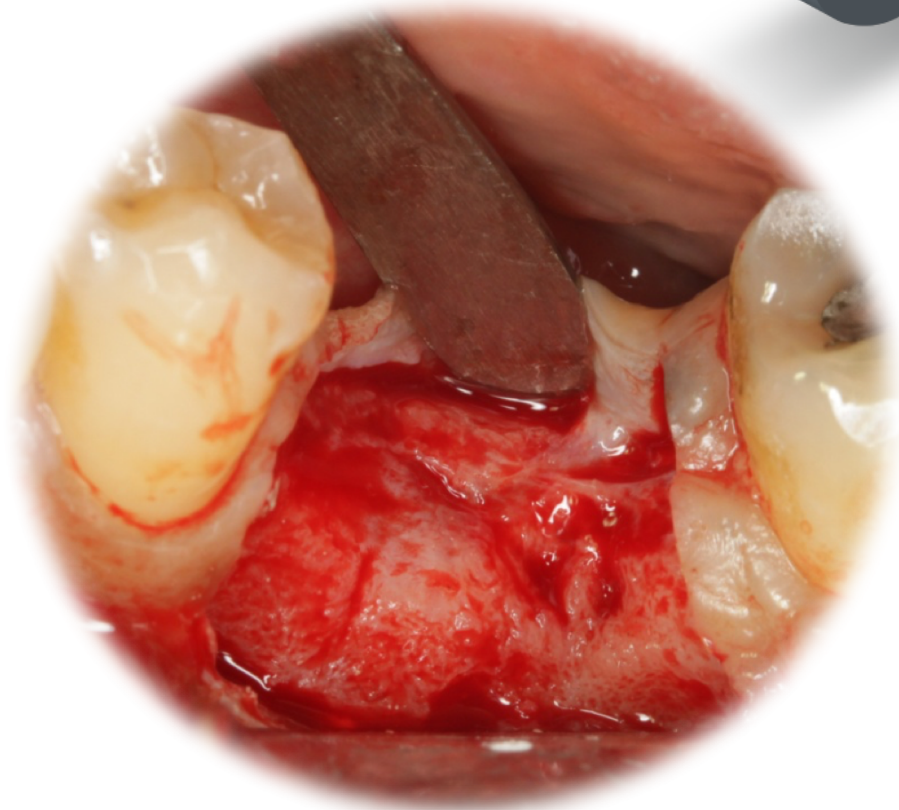


Suture removal one week p.o




12 weeks p.o

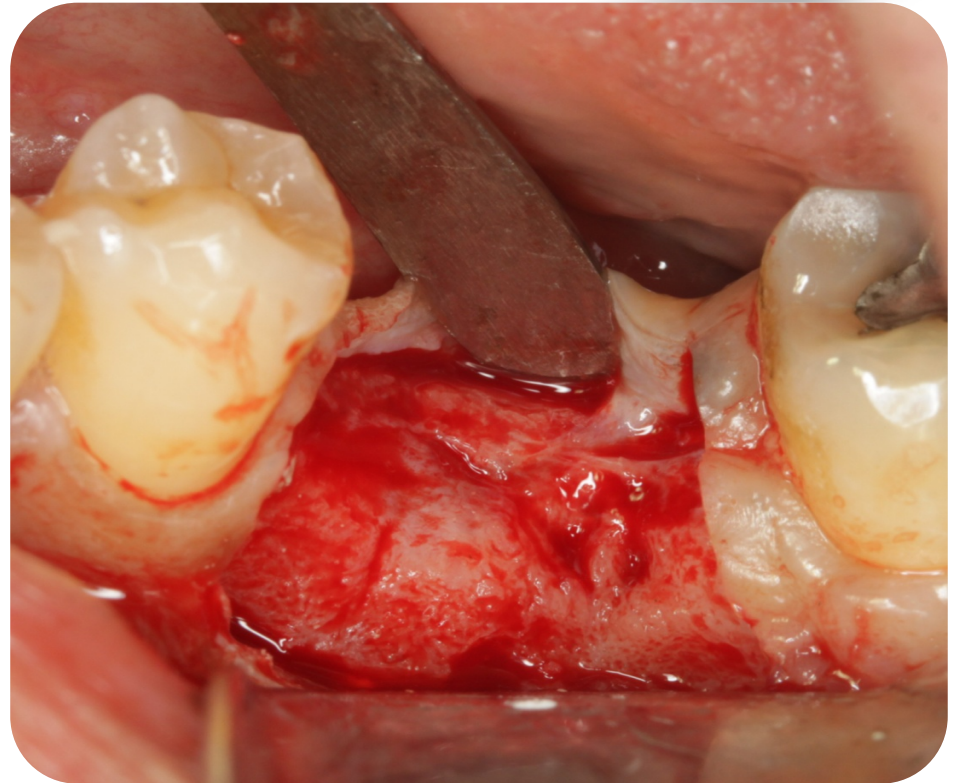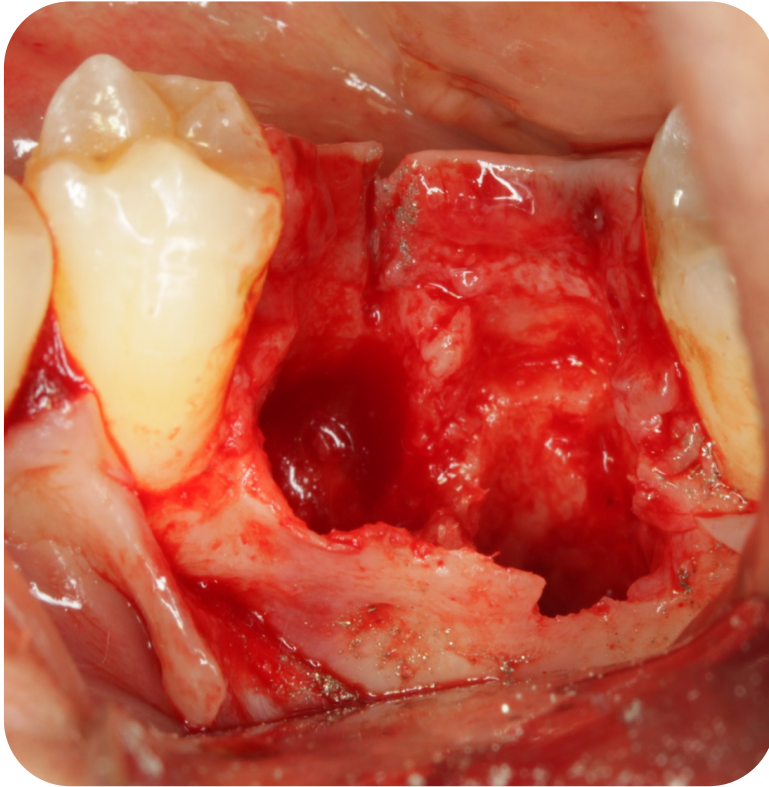

Bond Apatite®
Bone Graft Cement



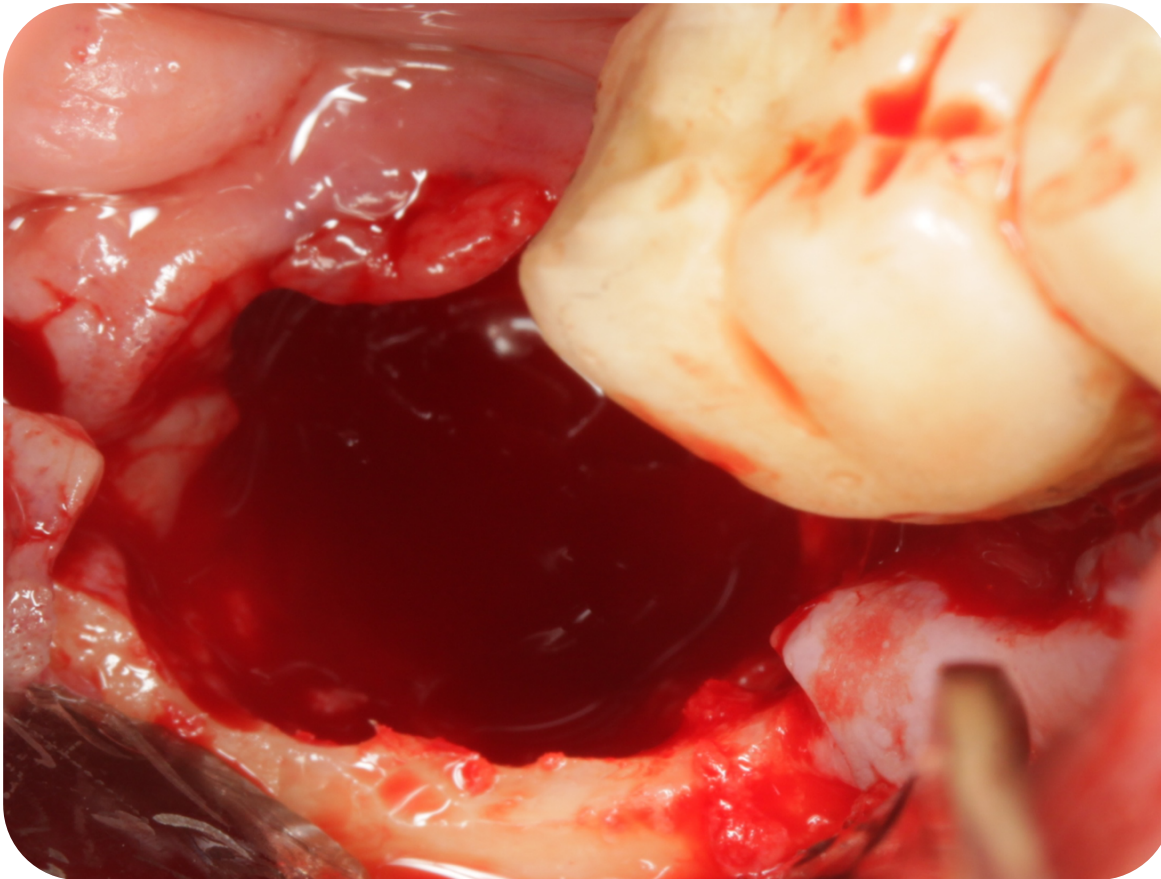
New bone formation



Augma
BIOMATERIALS



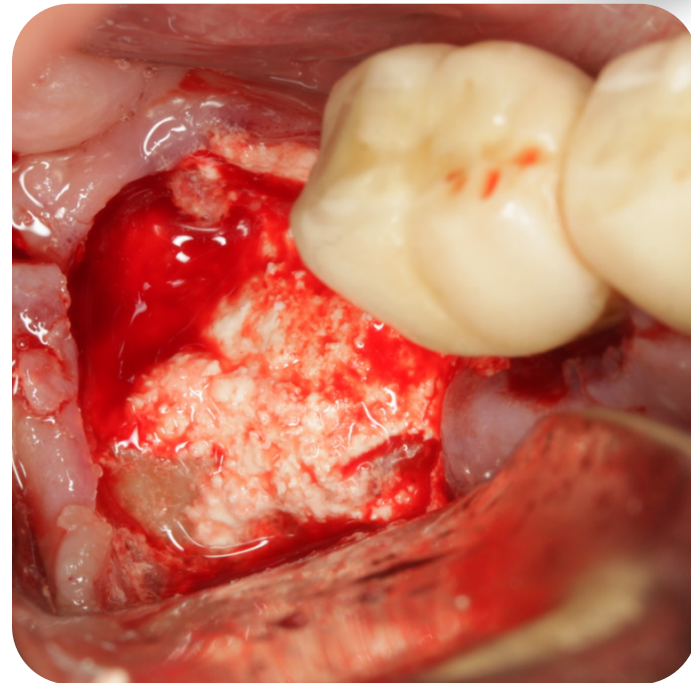
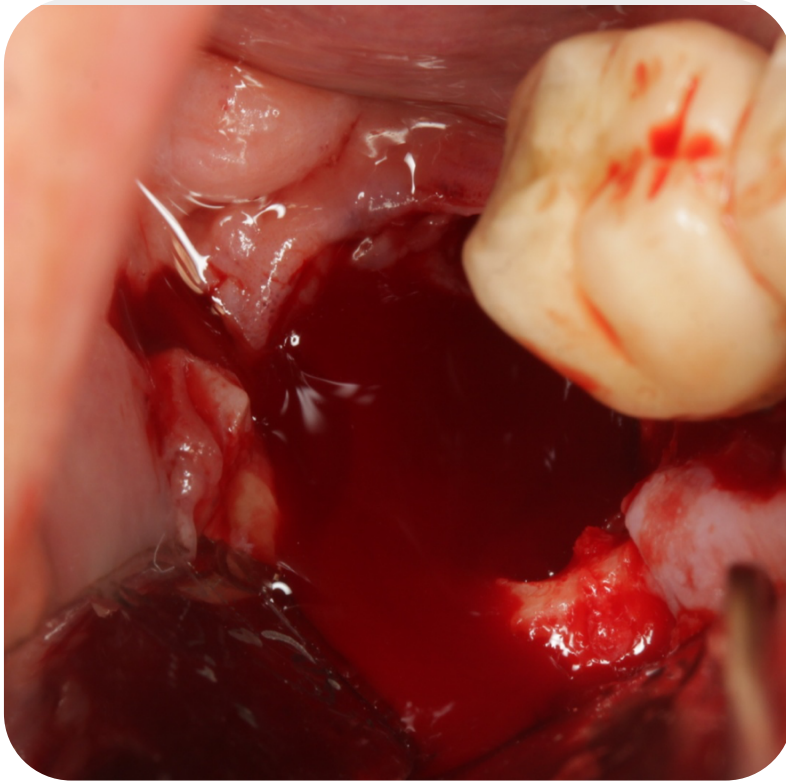

***Using 3D Bond™ and Bond Apatite® as excellent haemostatic
and augmentation material***




Before augmentation

3D Bond™
Graft Binder Cement

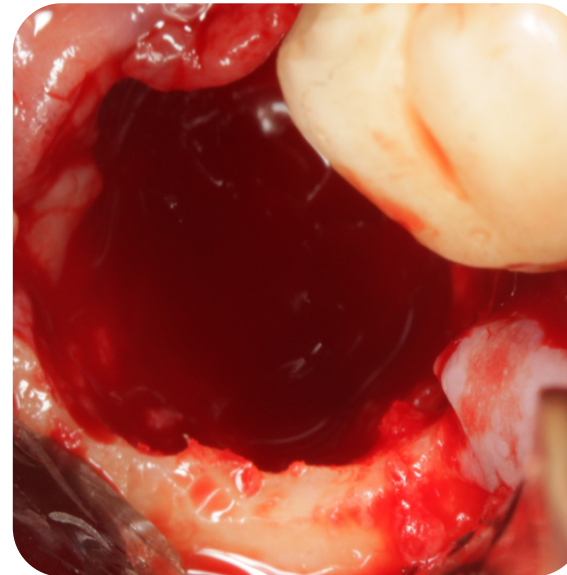

Augma
BIOMATERIALS



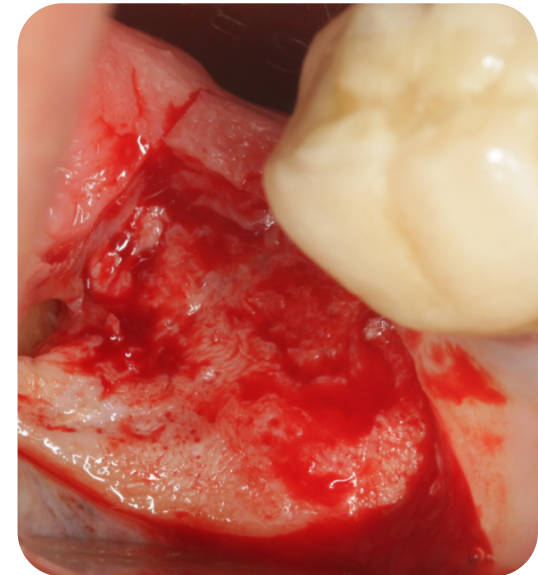
Bond Apatite® in place



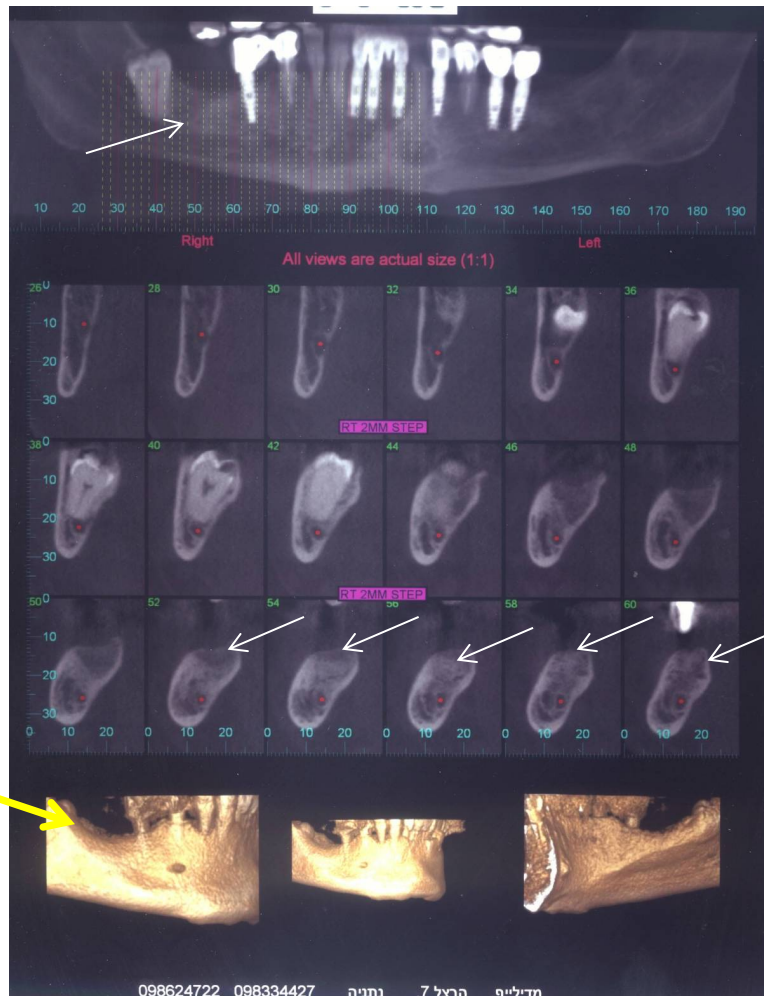
After 3 months



Before

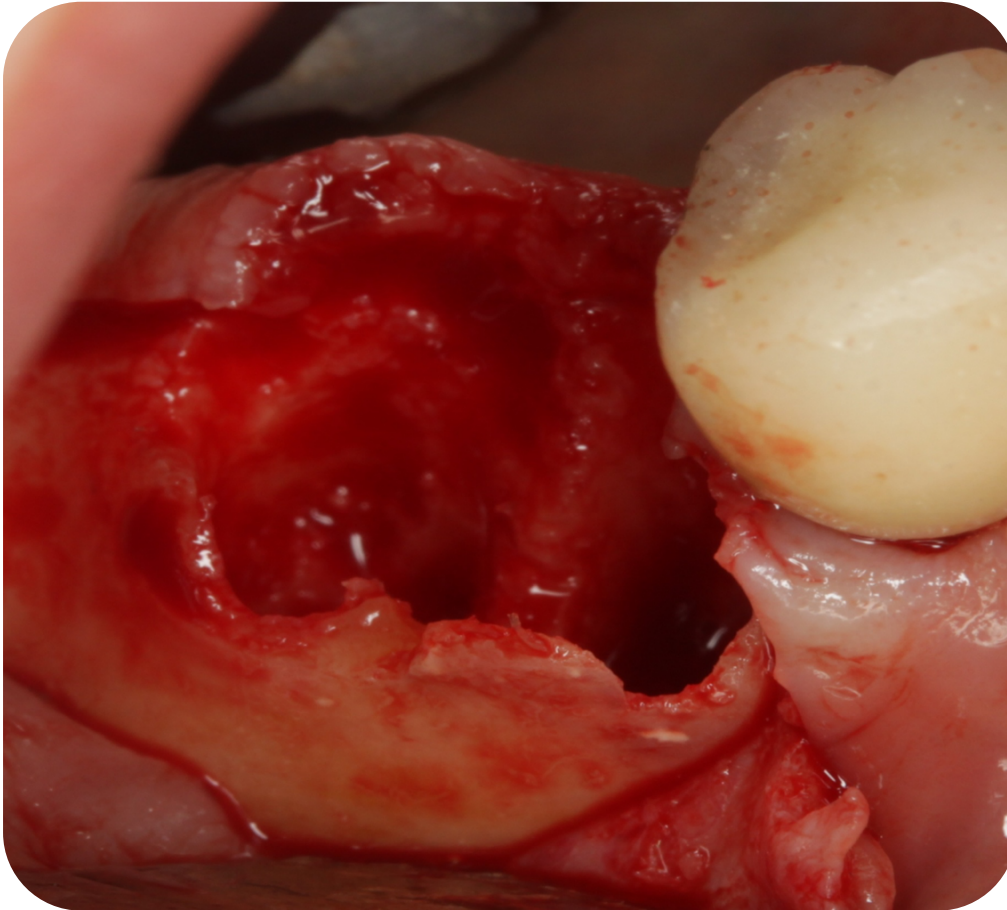



After



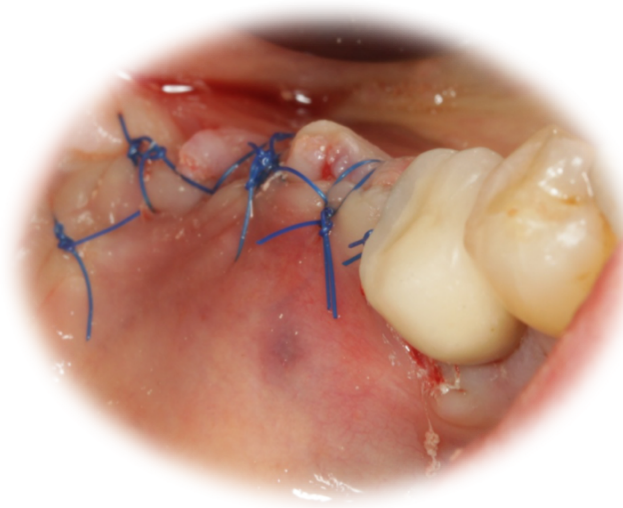
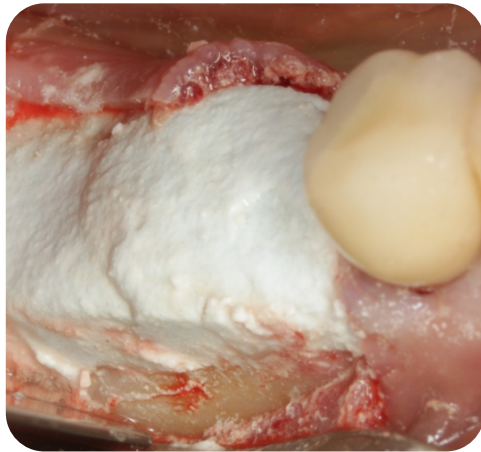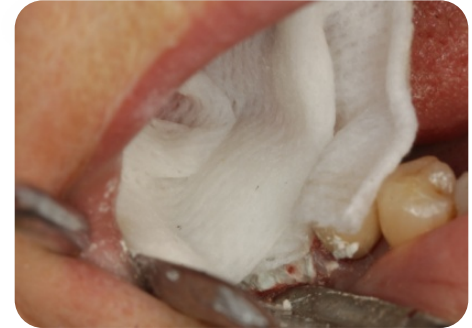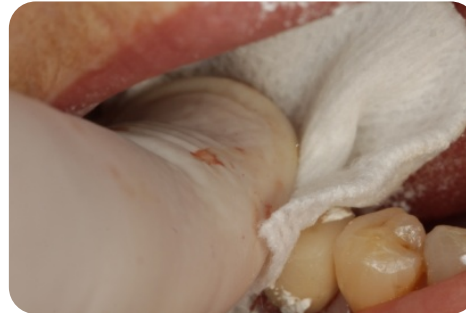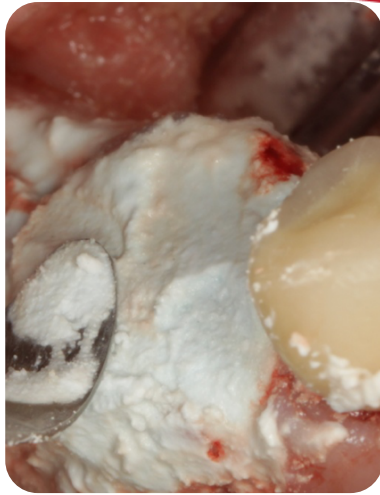
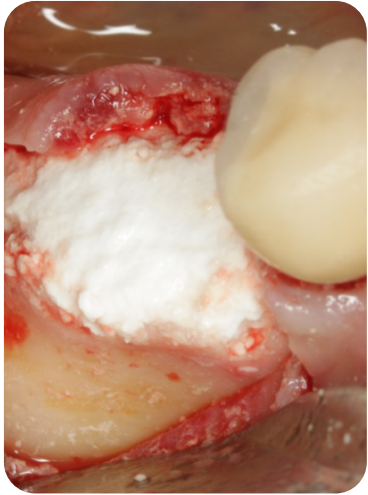

Bond Apatite®
Bone Graft Cement

Augma
BIOMATERIALS



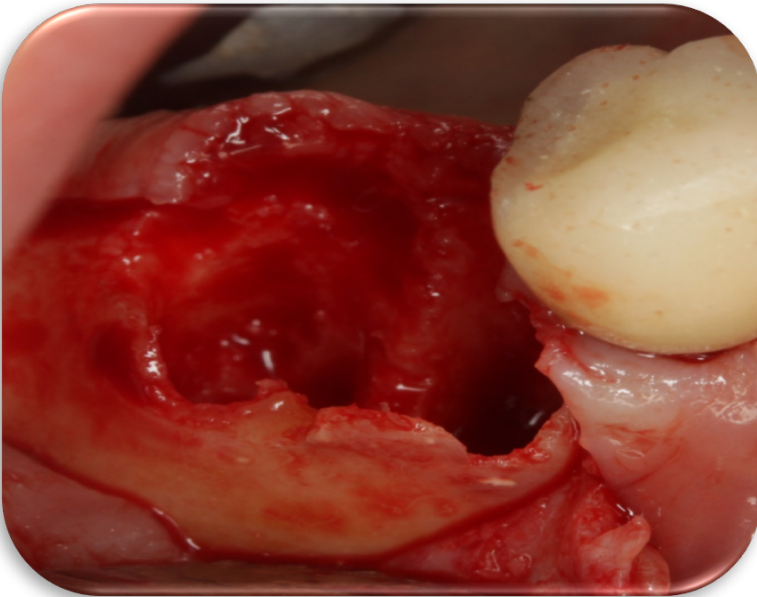

Large defect post extraction

Bond Apatite® application

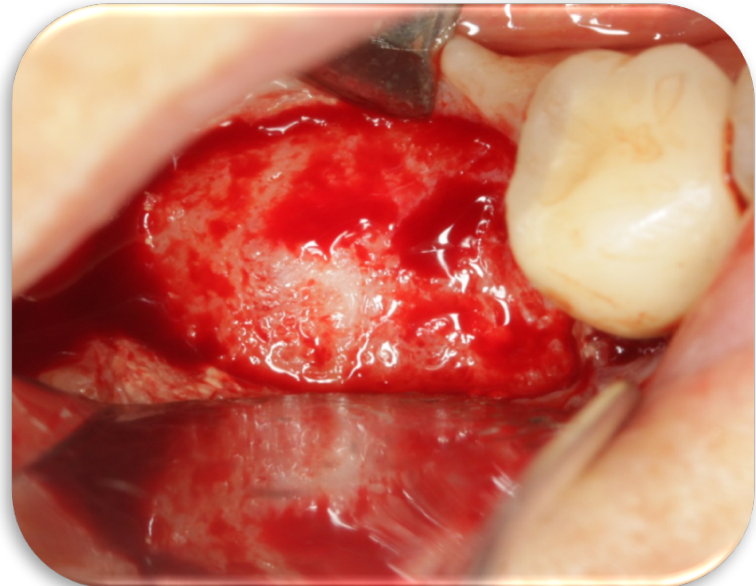


Bond Apatite®
Bone Graft Cement

Augma
BIOMATERIALS

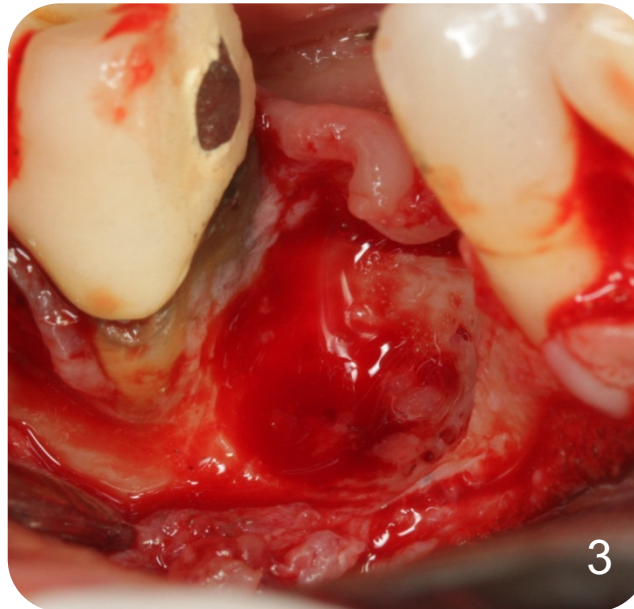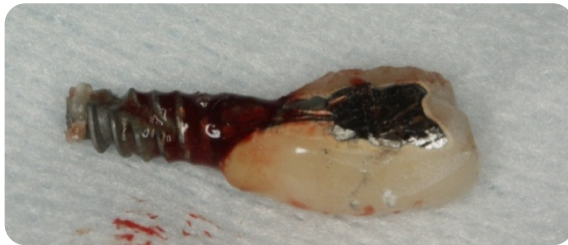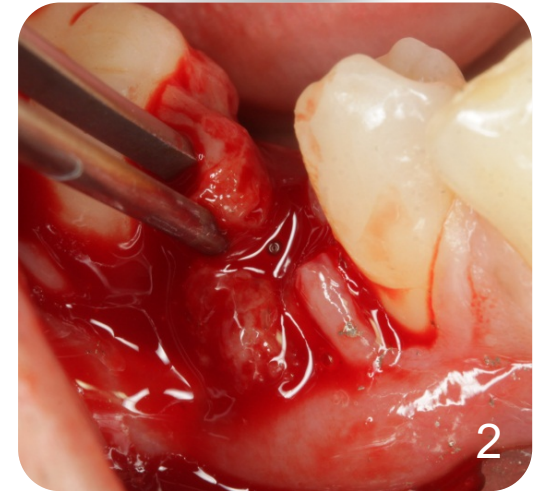


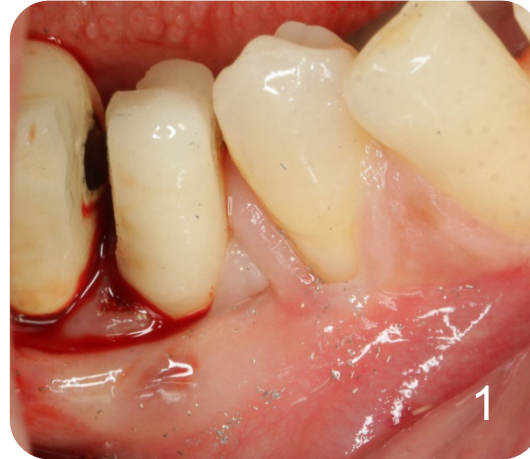
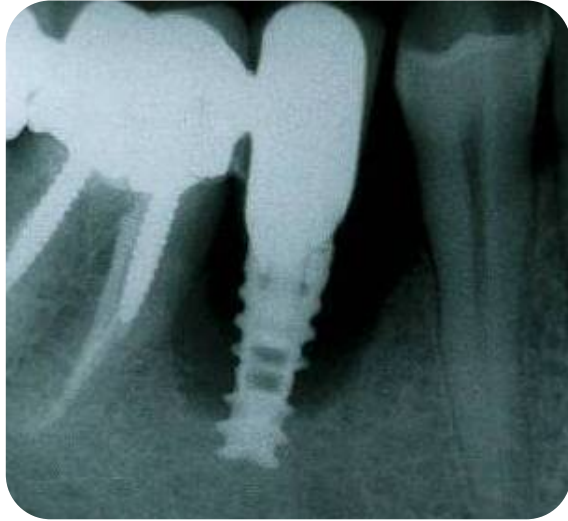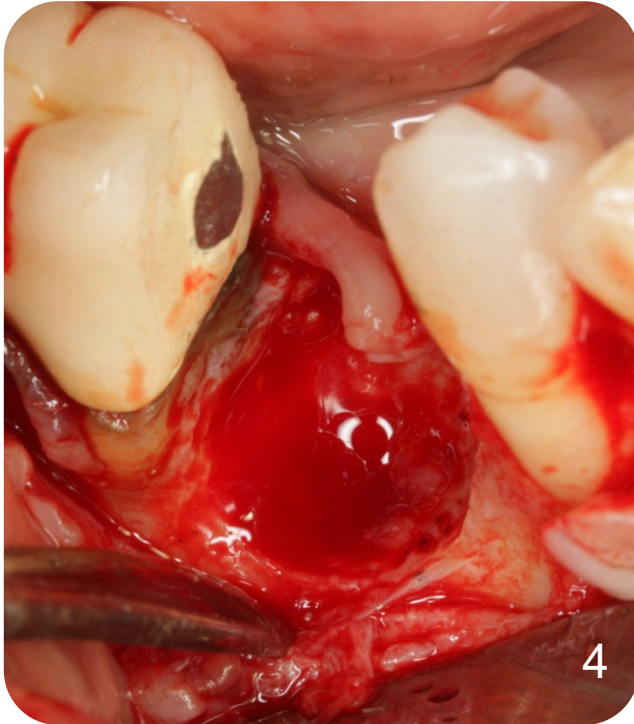

Before augmentation



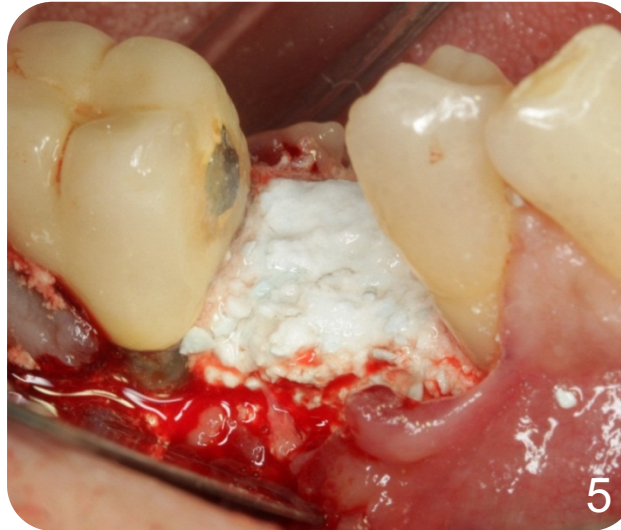12 weeks post op new bone formation can be seen

Augmentation post implant failure using Bond Apatite®

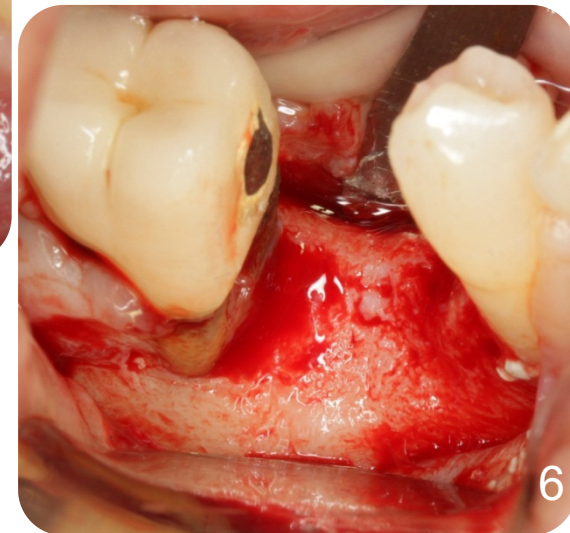




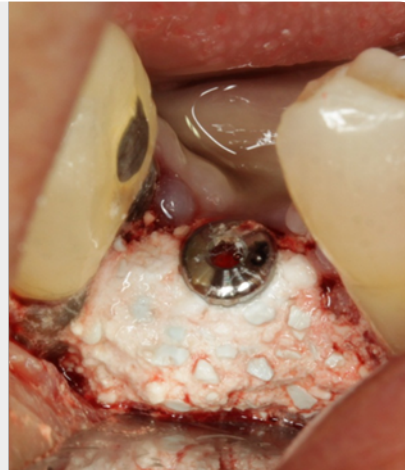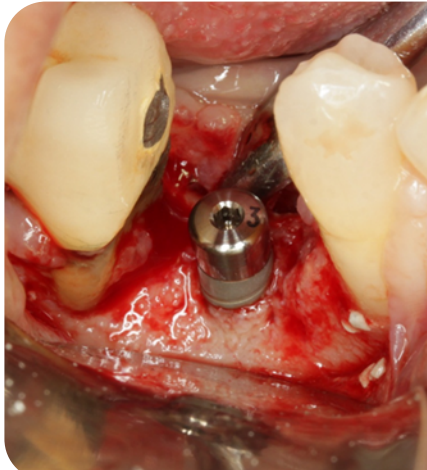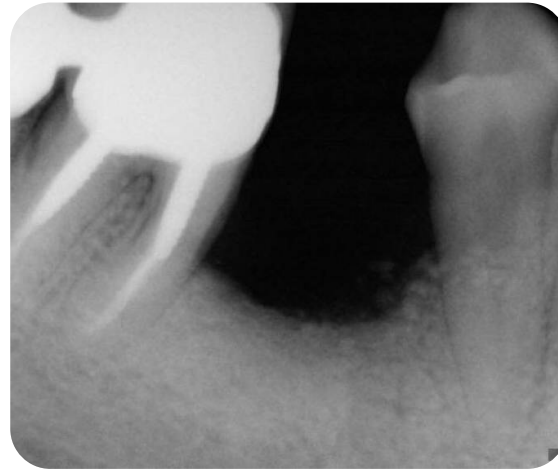

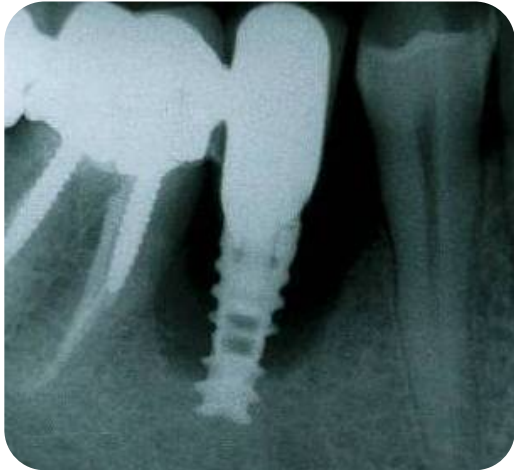Large bone deficiency
Post implant removal



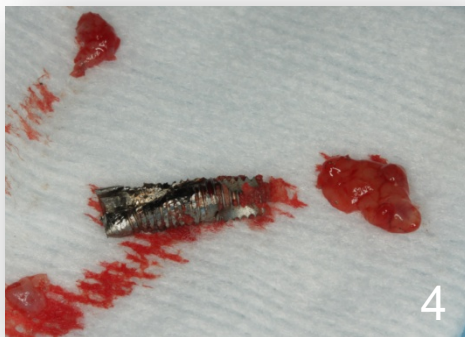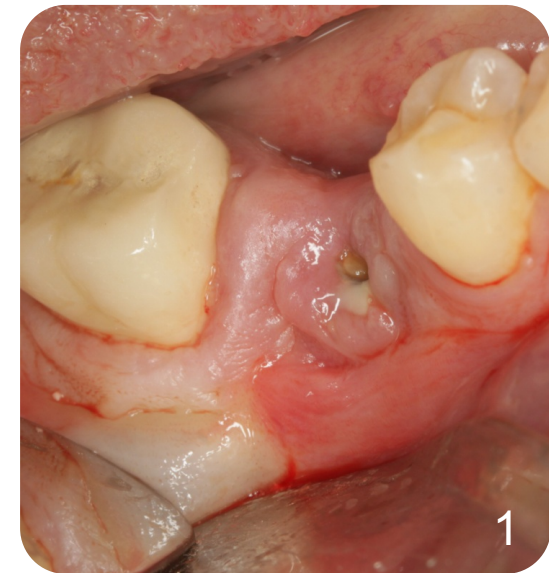
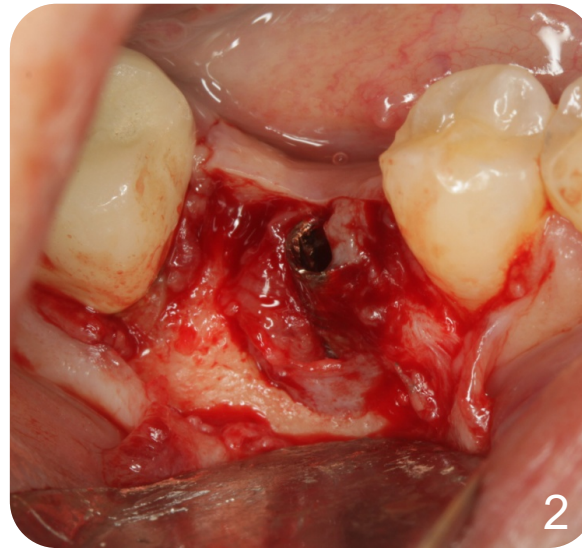
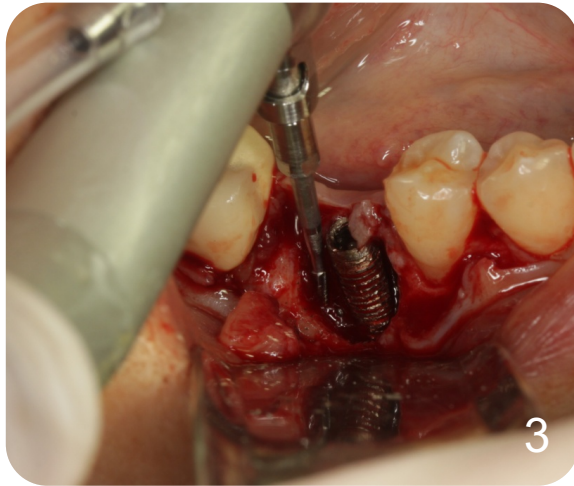
Bond Apatite® in place



New bone formation 3 month post op



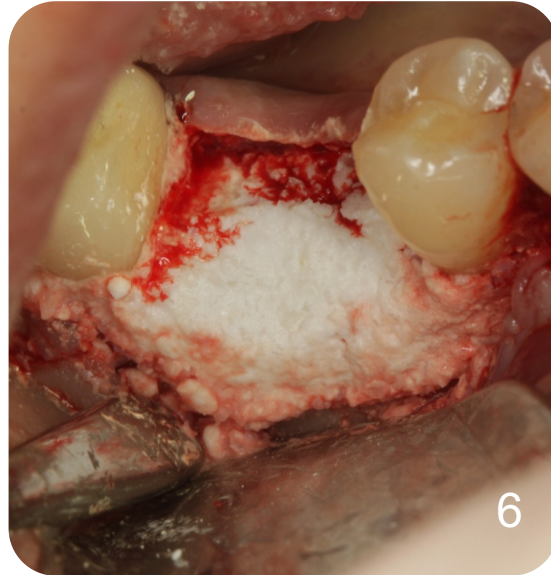
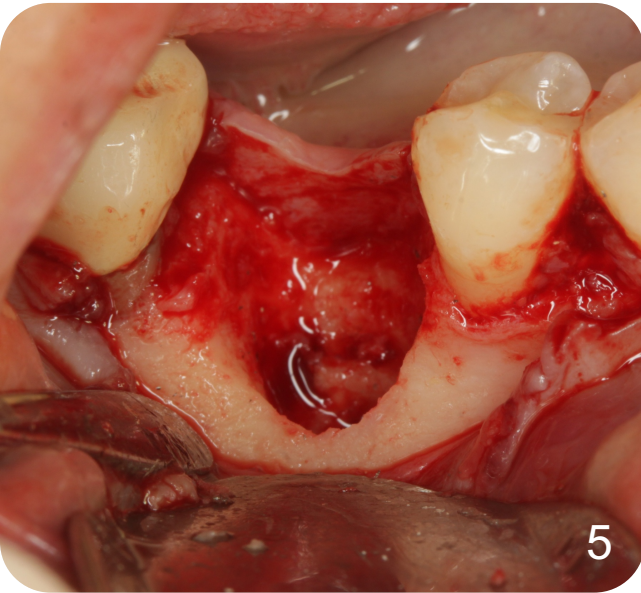

Removal of broken implant due to prosthetic failure



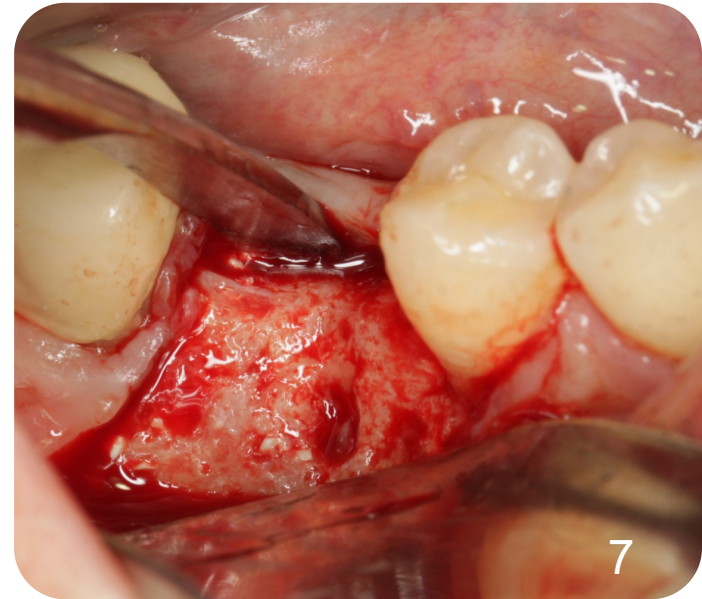
Bond Apatite®
Bone Graft Cement


Augma
BIOMATERIALS

Augmentation using Bond Apatite®



3 month post op



Soft tissue and radiographic appearance

