

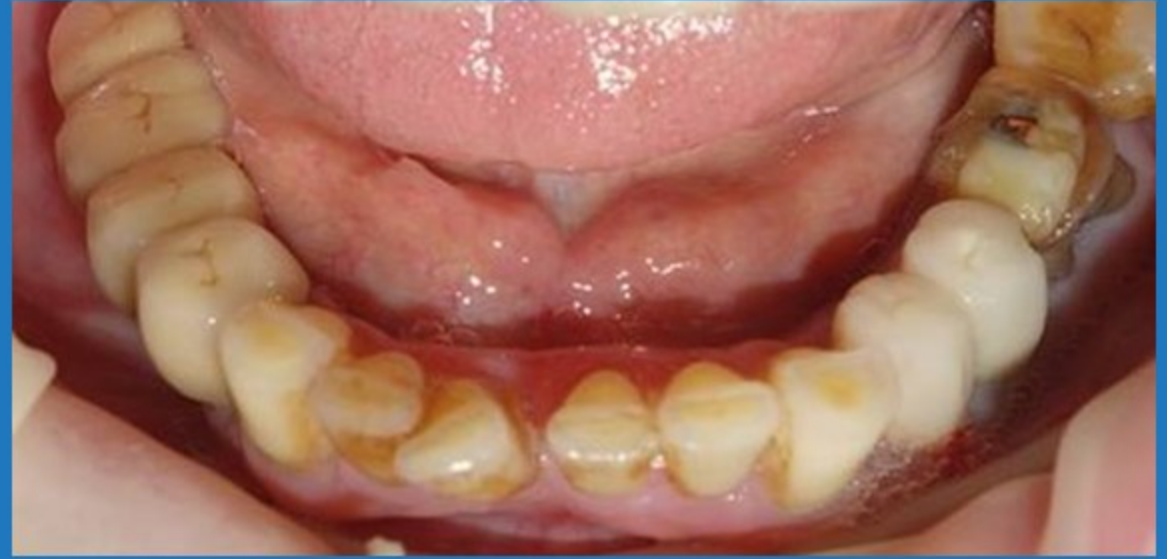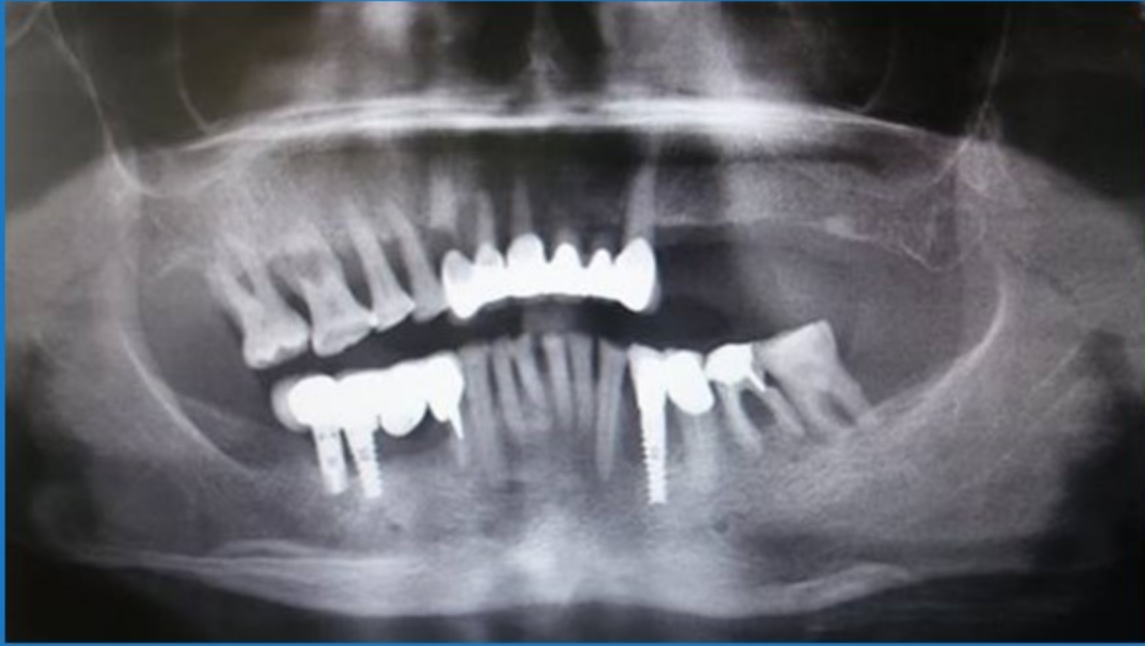Crest Preservation with Immediate Implant Placement

Dr. Ilia Mushayev

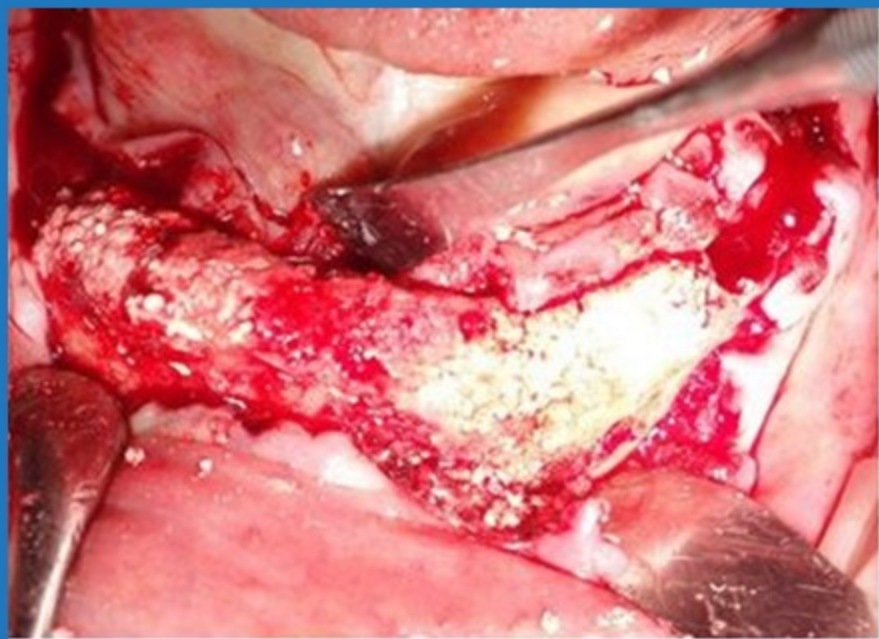
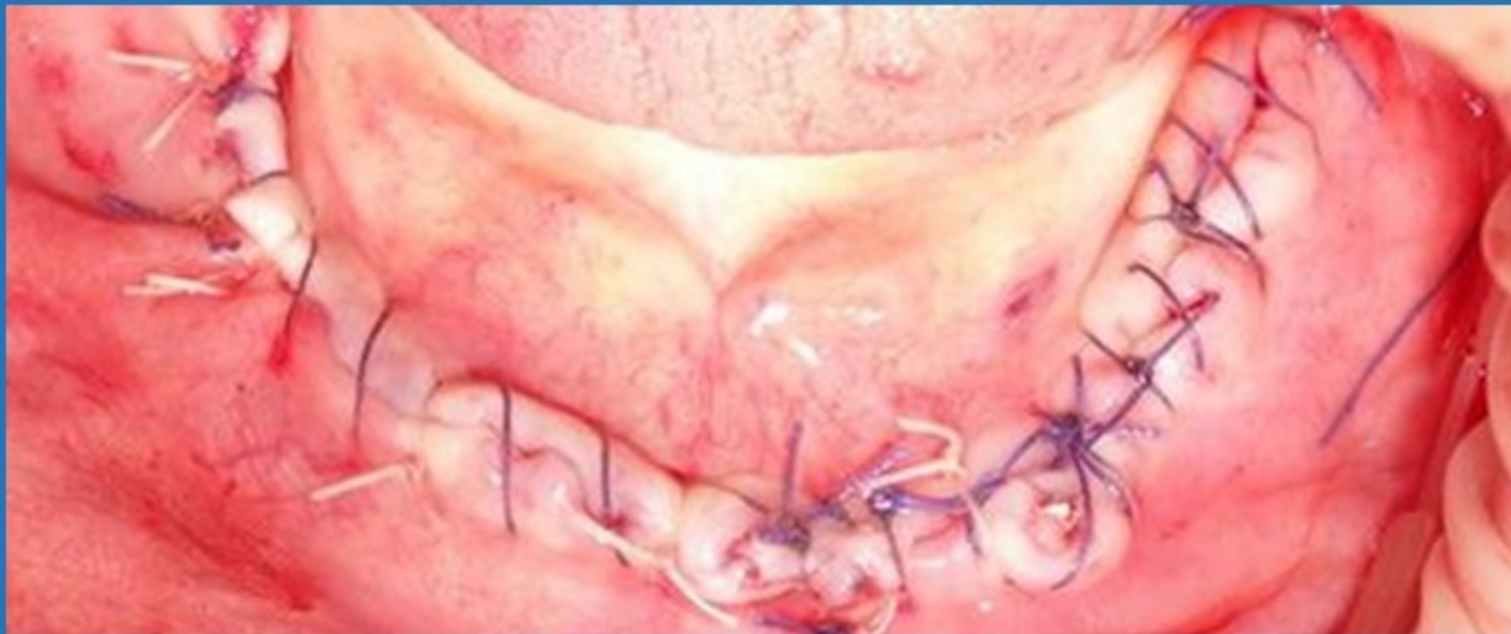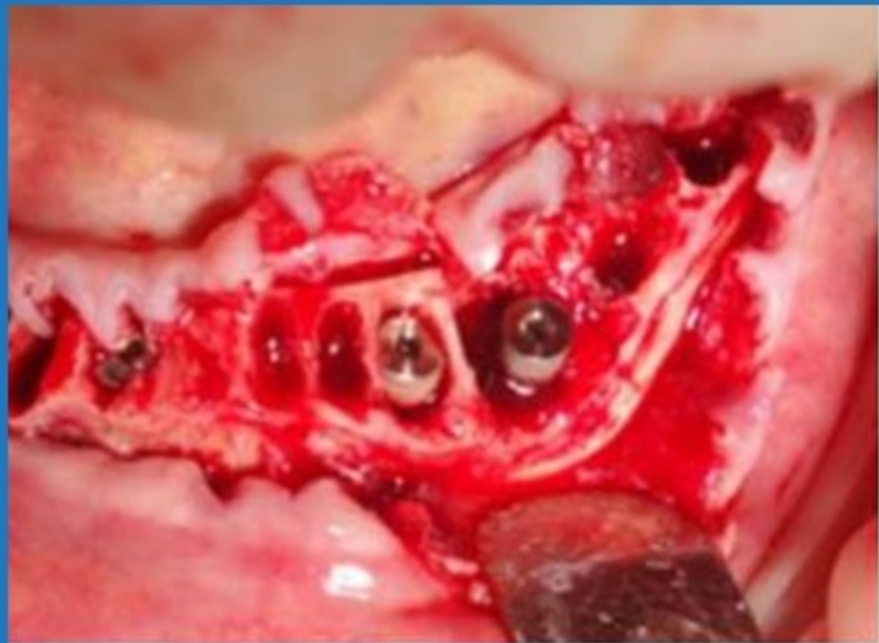


Crest Preservation with Immediate Implant Placement

After clinical and radiographic evaluation due to the poor prognosis of the existing dentition. The treatment plan was to extract all the existing lower teeth and in addition to removing the 2 failed implants 45,46 (29,30) while keeping implant 33 (22) in place. Thereafter, perform an immediate implant placement of 3 implants and simultaneously augment and preserve the crest. The final prosthetic plan was to provide the patient removable overdentures on those implants.



Pre op



Day of surgery

3 Months post op.

- Healing went uneventfully and re-entry took place after 12 weeks.
- During re-entry a diamond bur was used to remove excess bone grown above the cover screws, integration of the implants was achieved and ball attachments were connected to the implants

