

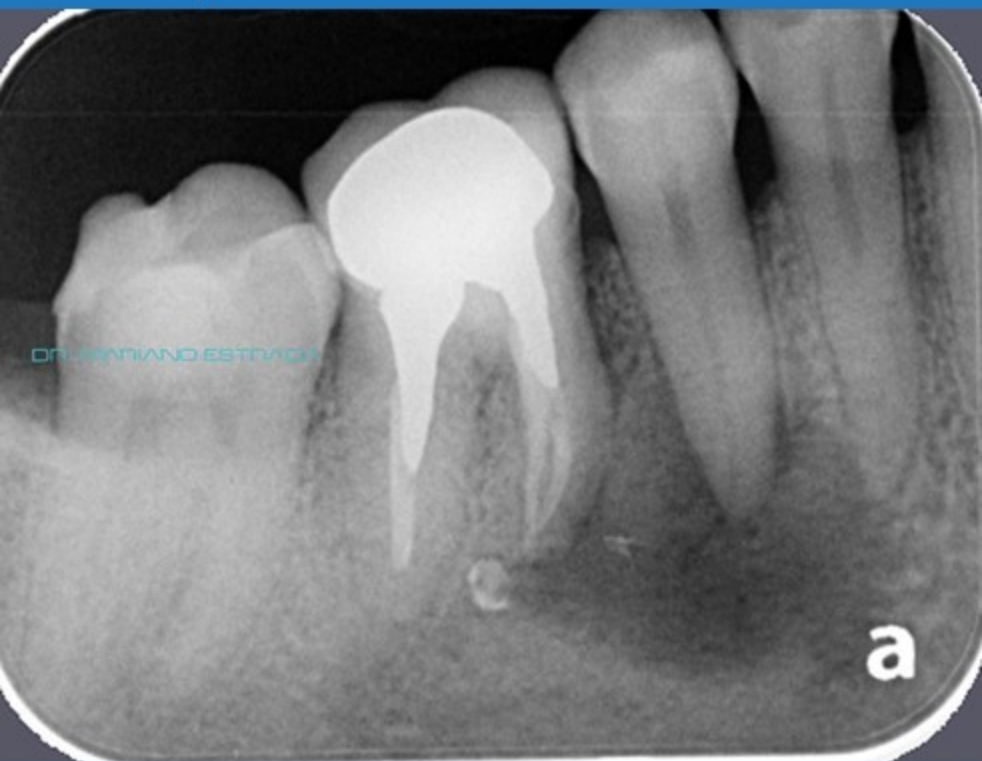

**Augma™**  
BIOMATERIALS

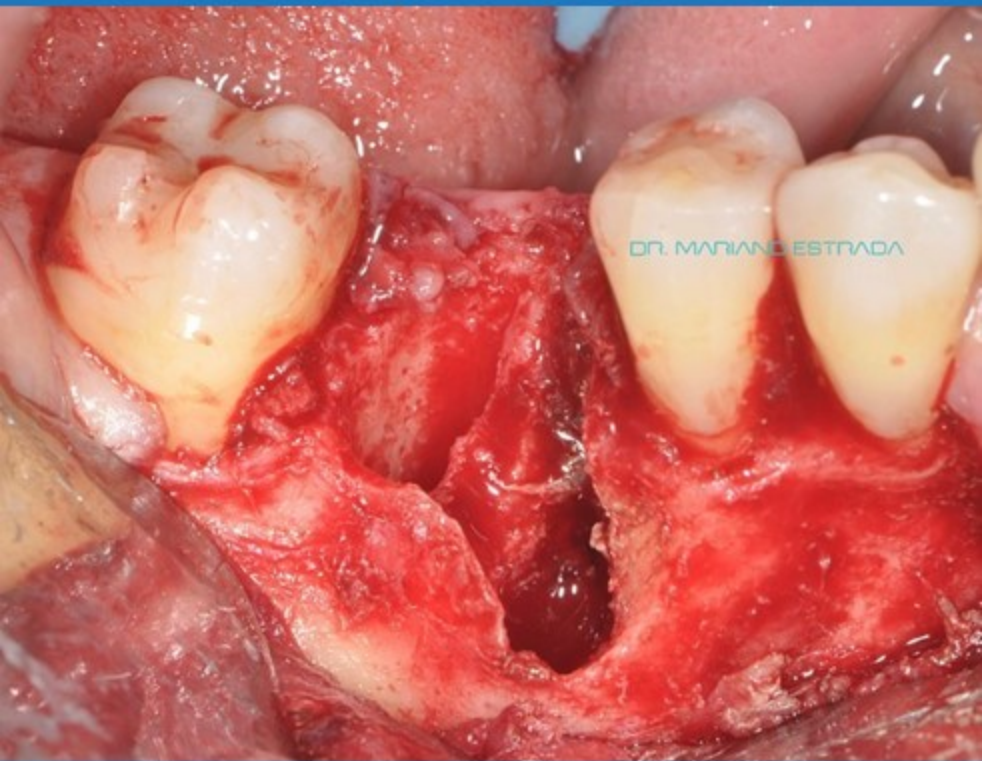# **Mandibular 1st Molar with no Buccal Wall**

**Dr. Mariano Estrada**

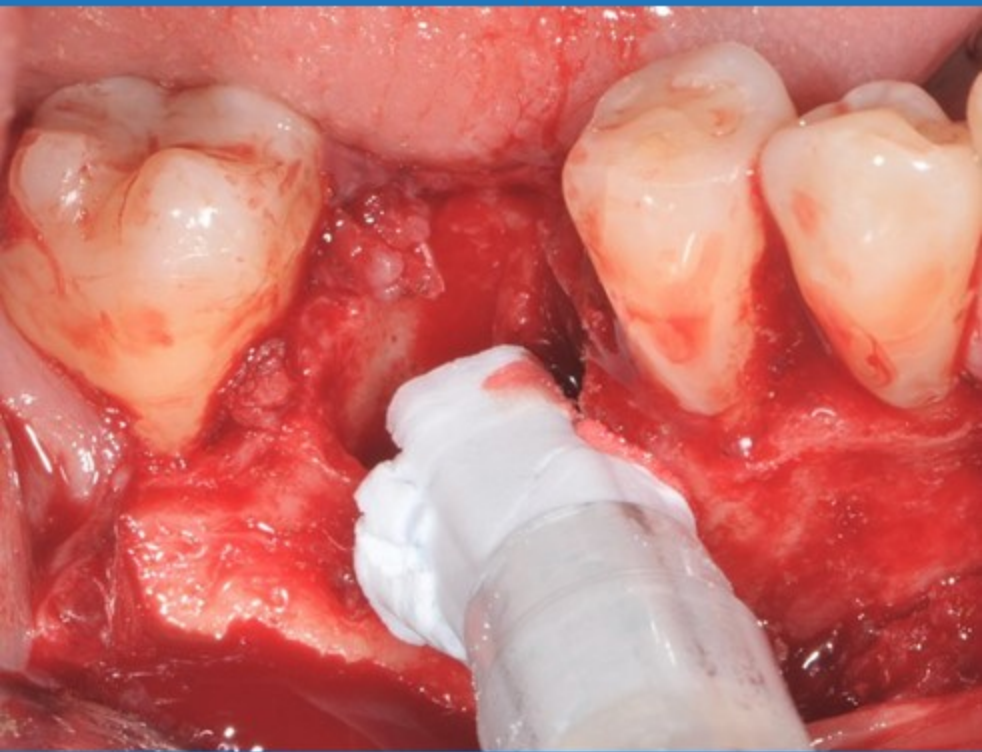
# Pre-op – 1s Molar with Infection



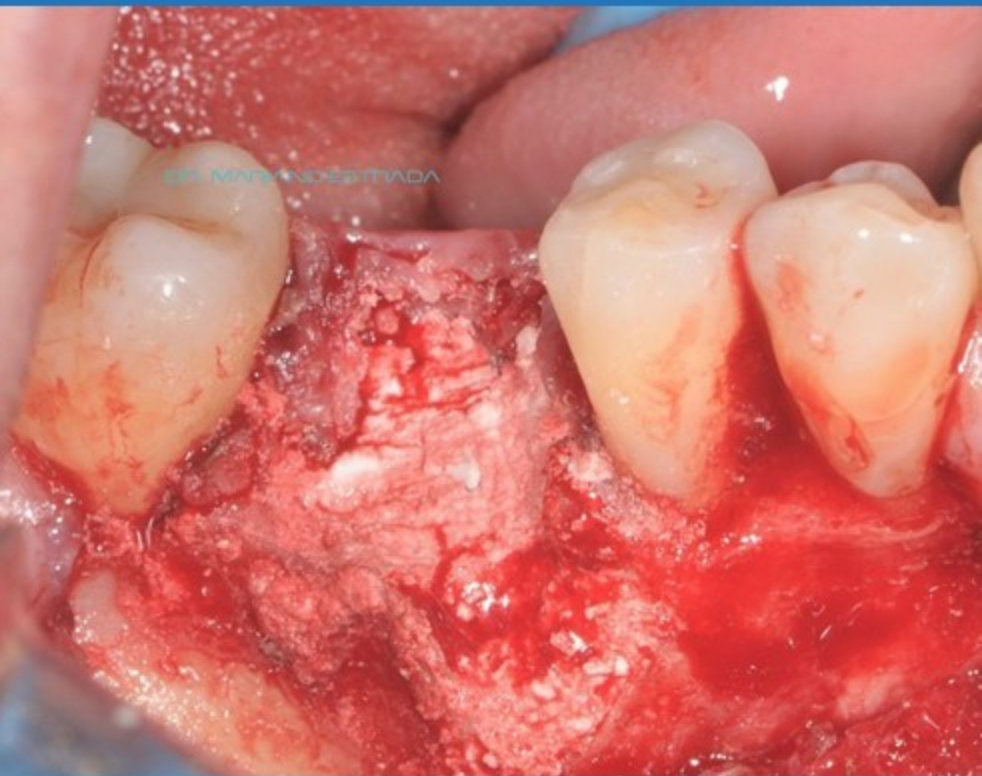# Missing Buccal Wall



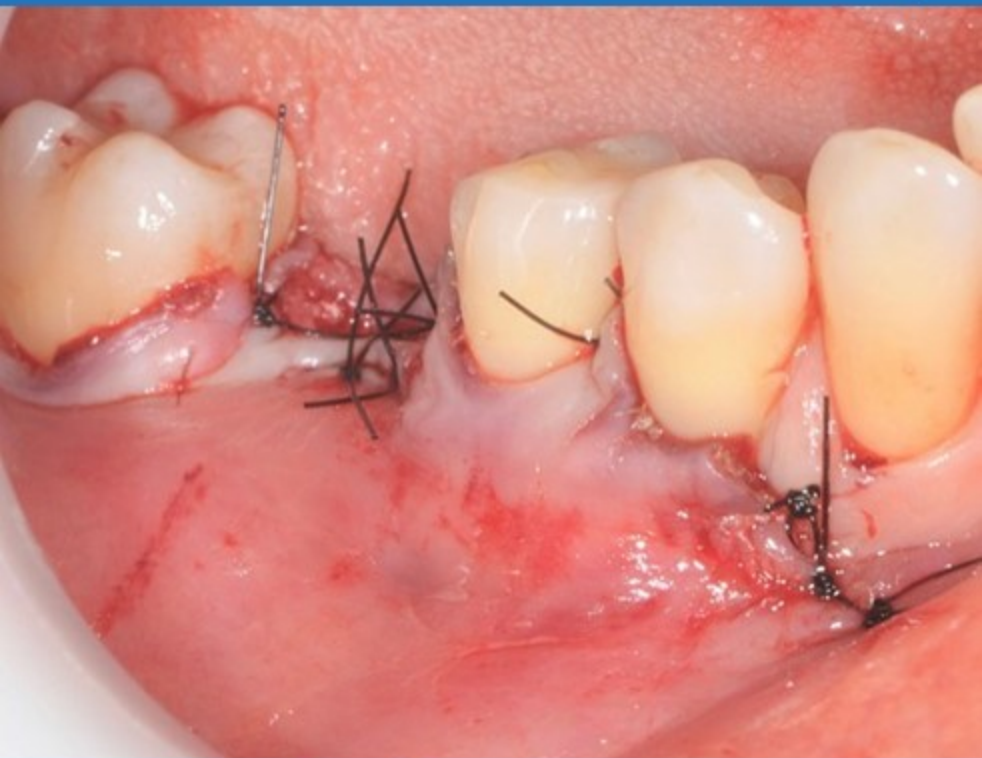# Bond Apatite



# Compression of the Bone Cement

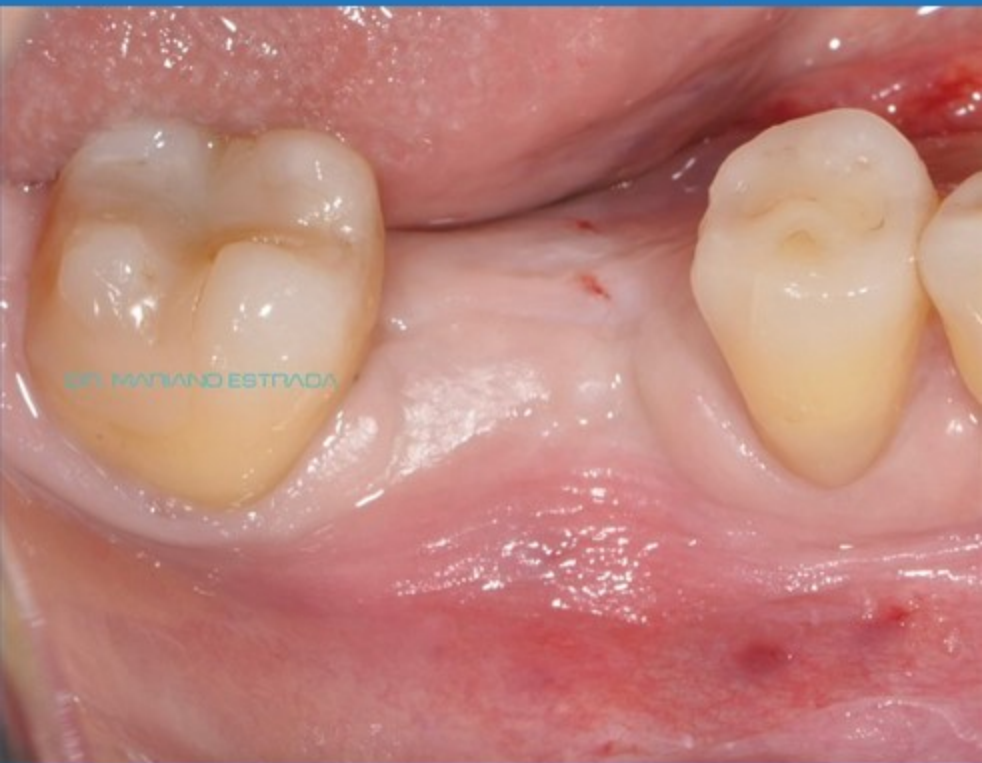

# Suture with Tension on the Flap

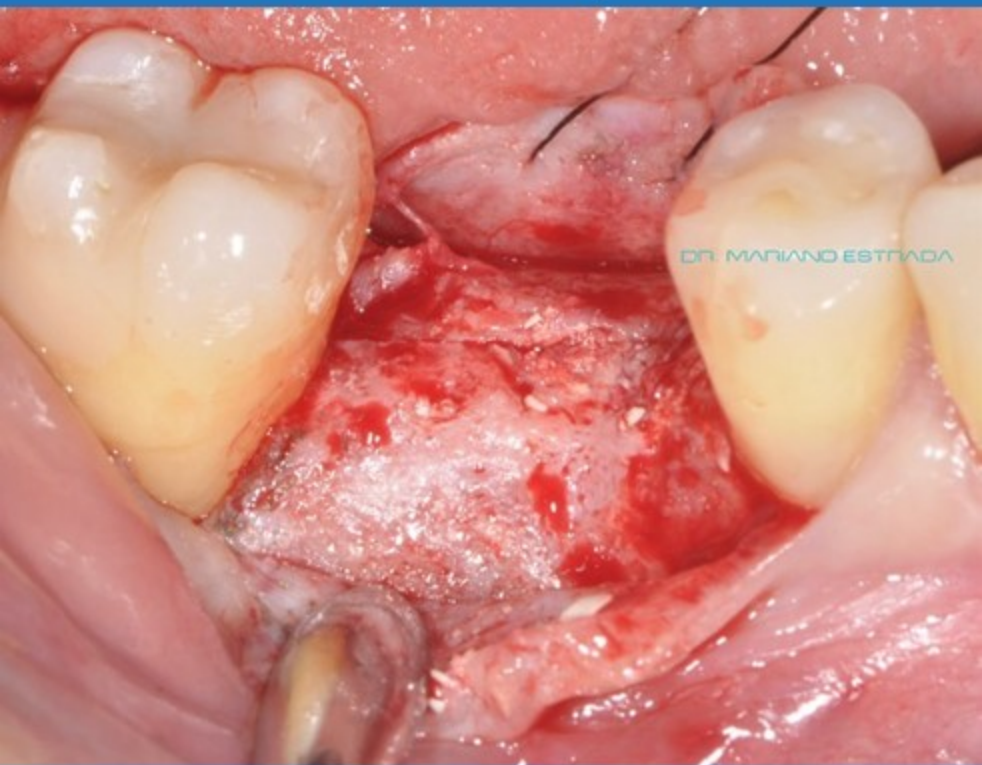

No Membrane

4 Months Post-Op



# Re-Entry





# Implant in Place



