

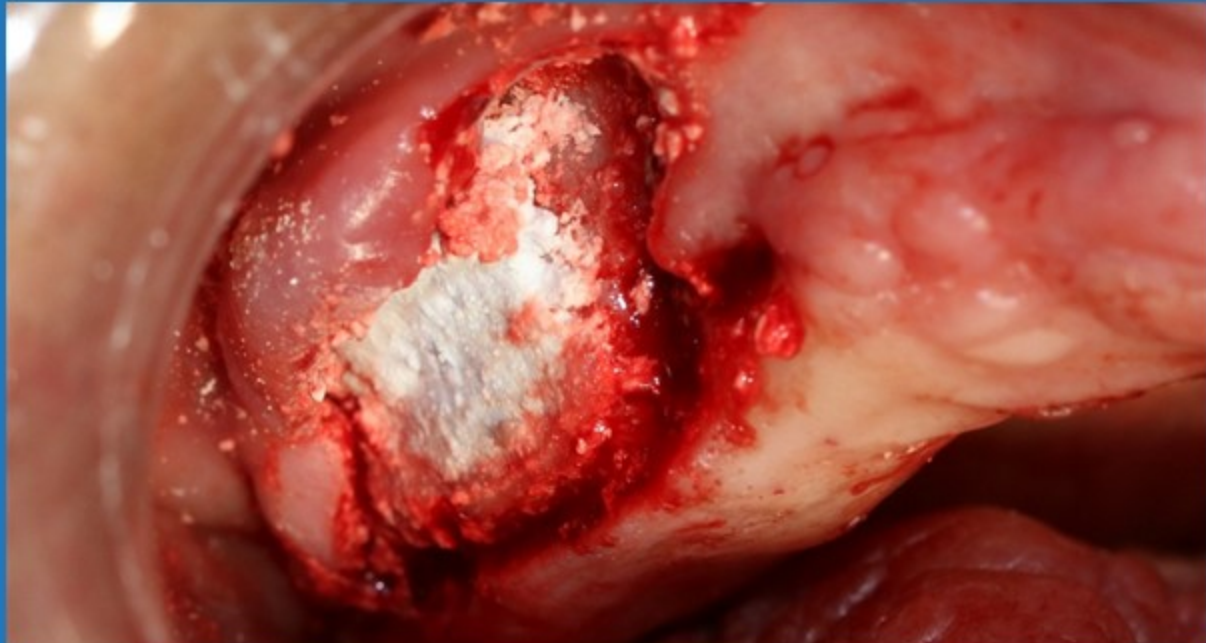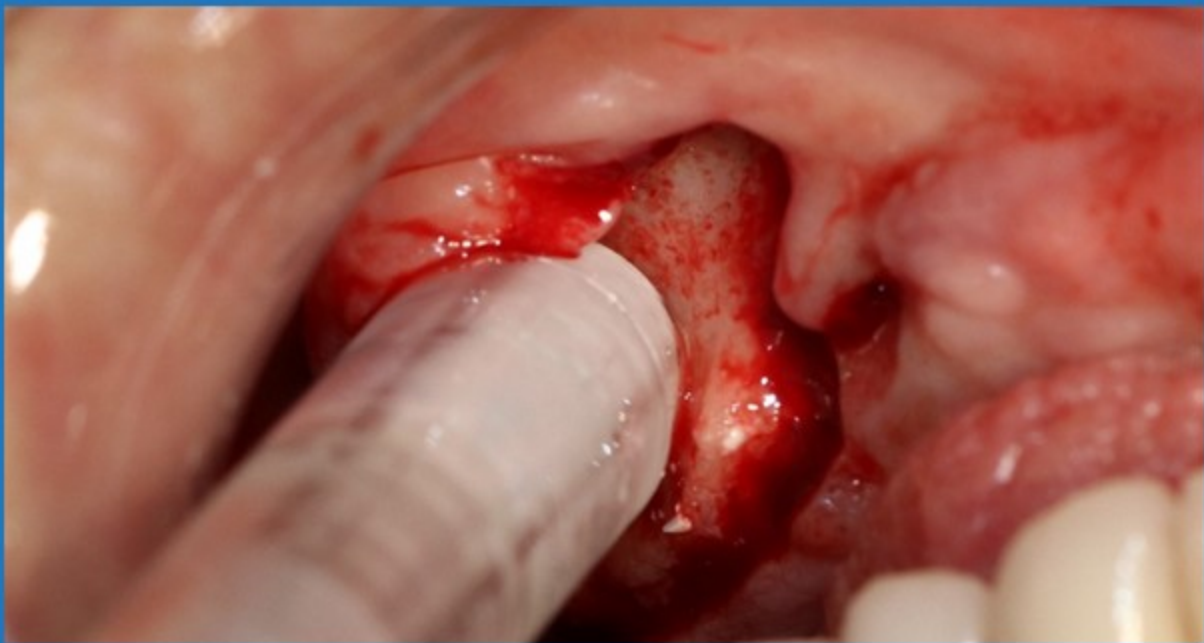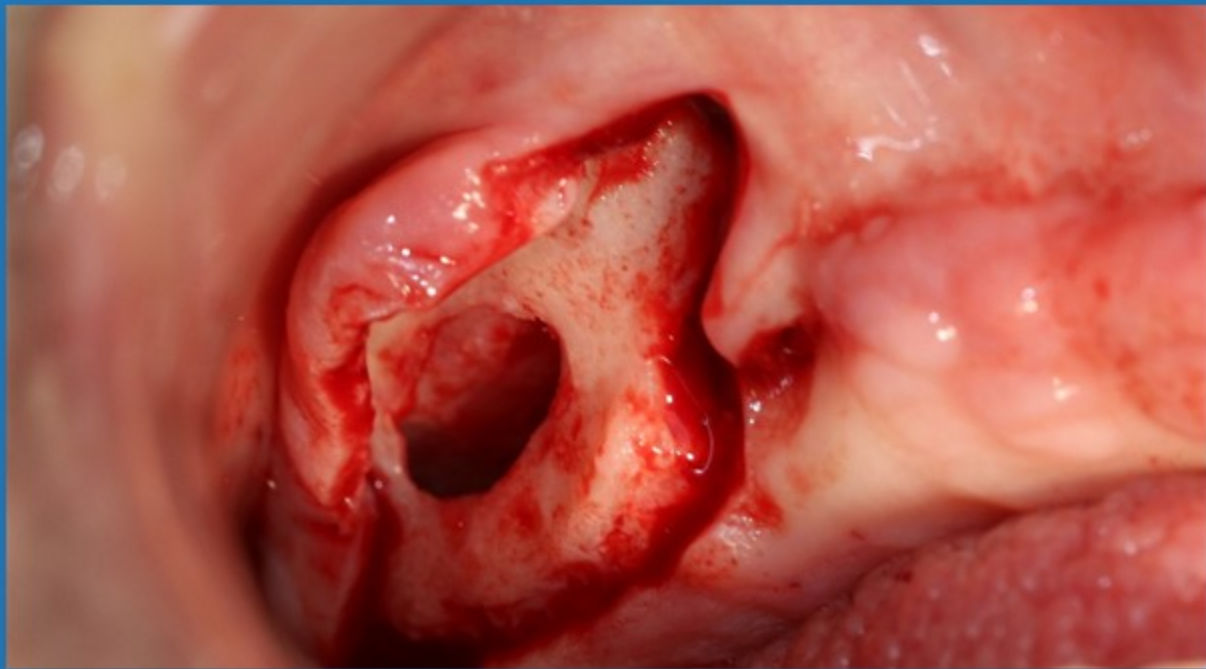
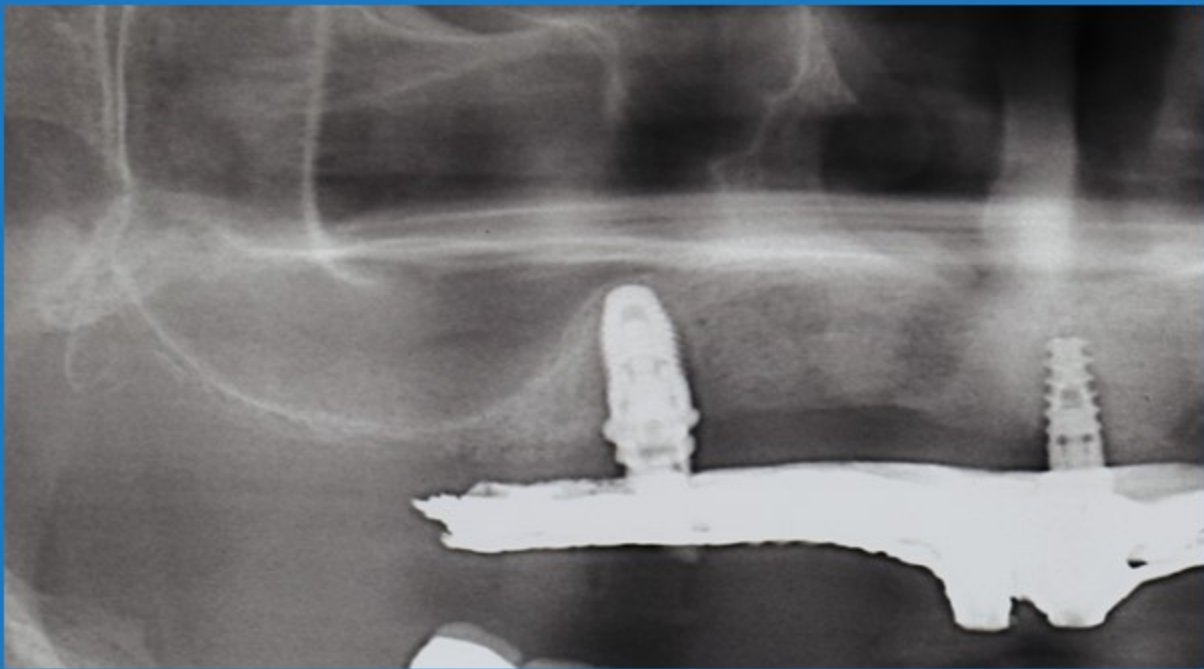
Open Lateral Sinus Lift

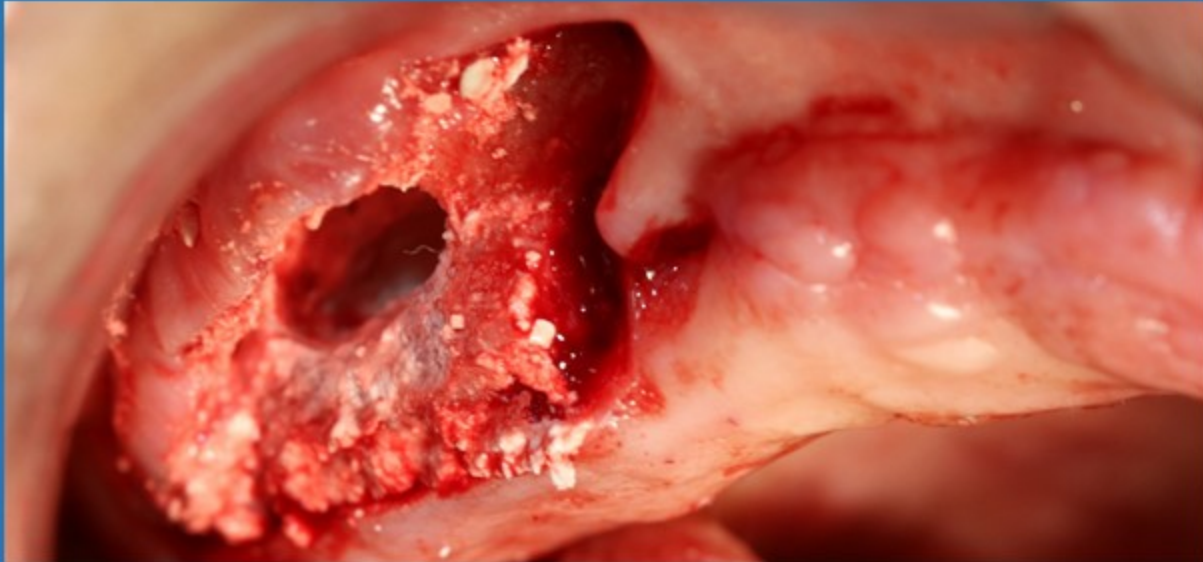
Dr. David Baranes



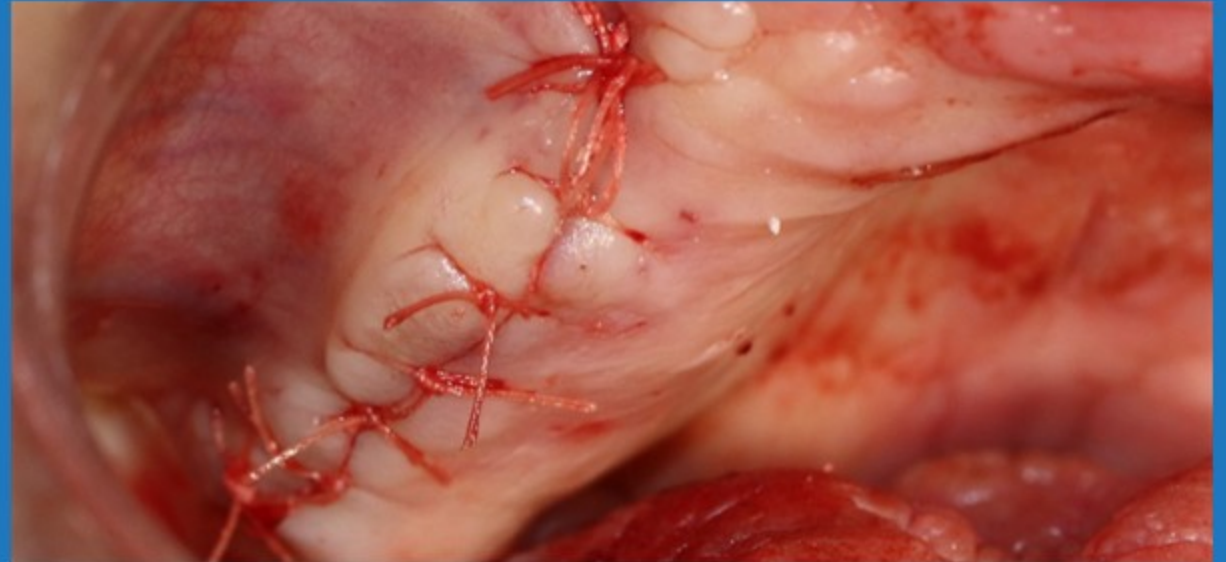
Open Lateral Sinus Lift

65-year-old patient came to consult for implant treatment. The patient had a first implant treatment twenty years ago and then lost her implants little by little. Dr. Baranes decided to start by raising the floor of the sinus laterally - right side then left side combined with Bond Apatite. The bone cement allows bone regeneration without the need to use of a collagen membrane. Only 4 months of healing, after the elevation of the floor of the sinus, were needed before implants were placed.



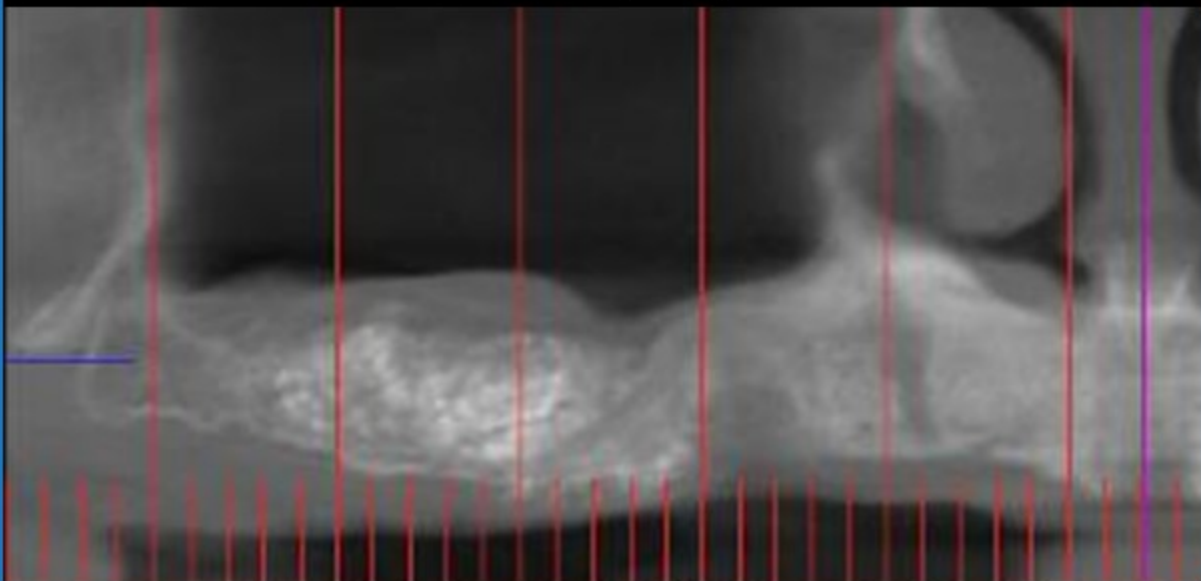


Day of surgery

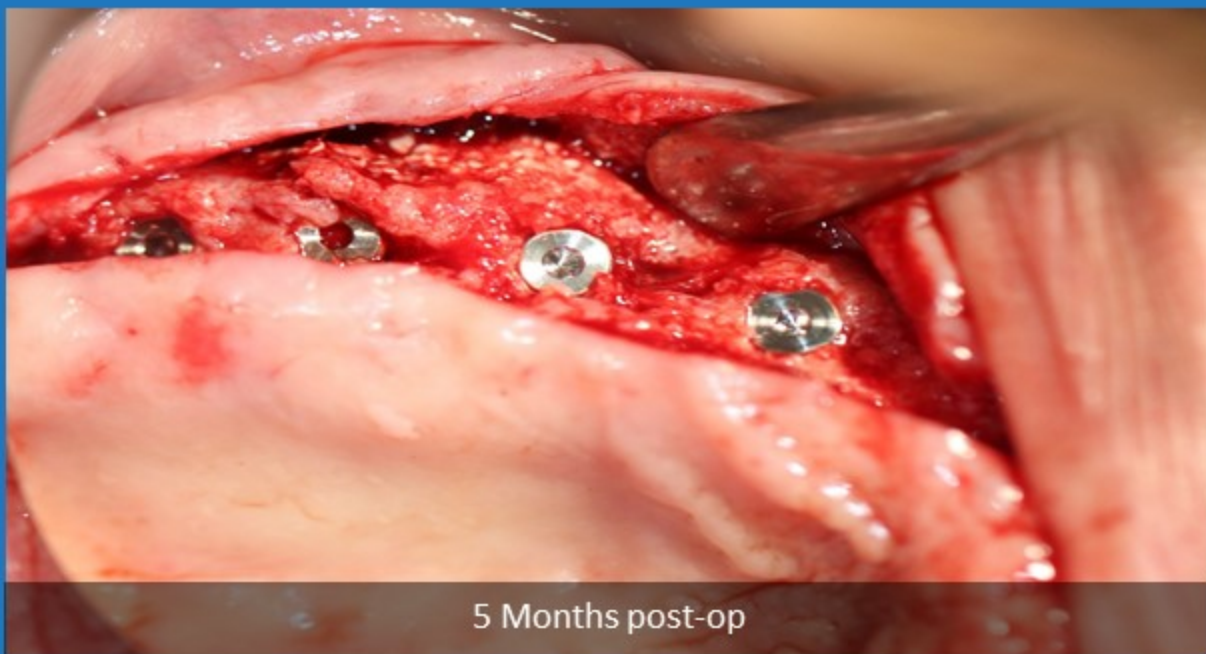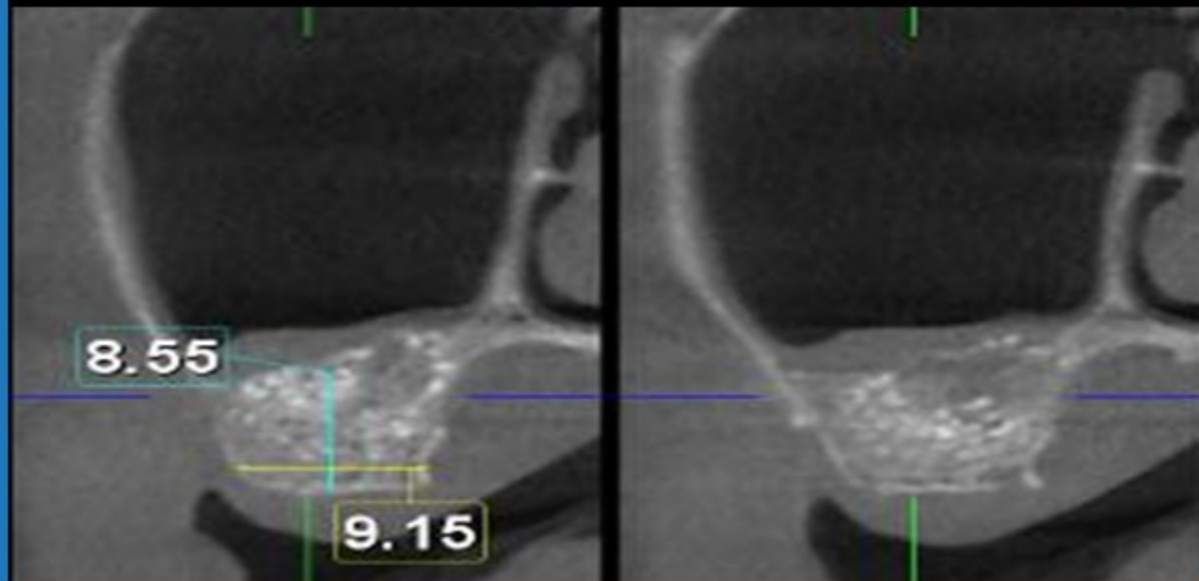


Immediate post-op

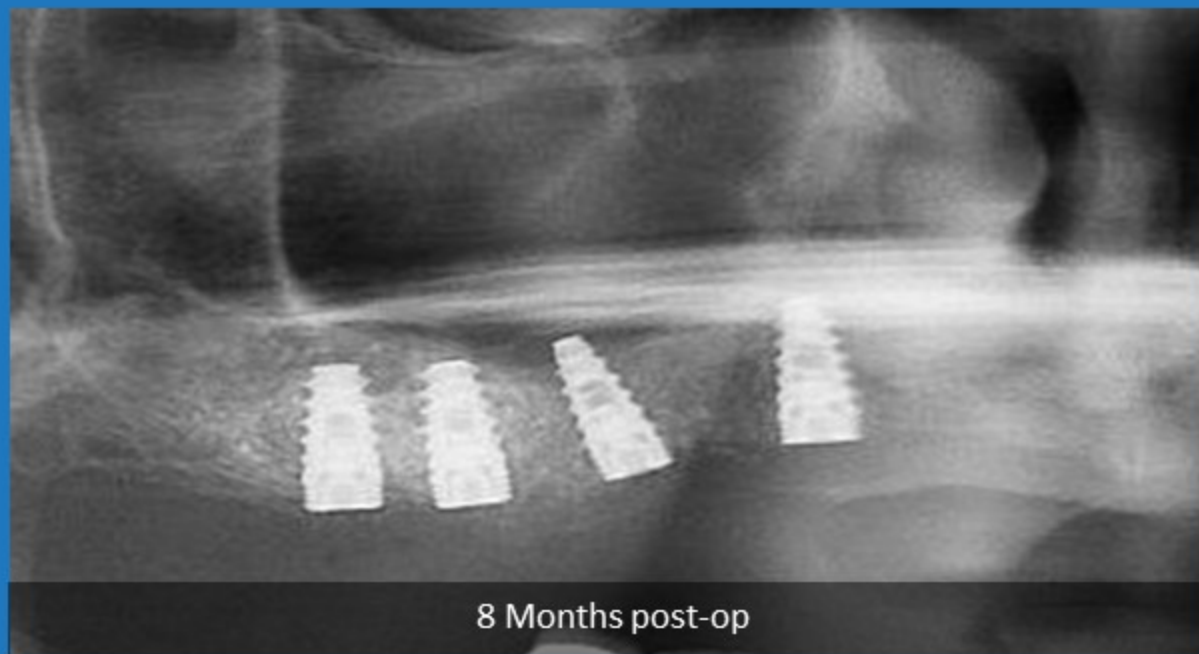5 Months post-op



5 Months post-op



5 Months post-op



8 Months post-op